


Fix-a-Nator[®]

A Fixed Bionator Technique

By Yosh Jefferson, DMD



Yosh Jefferson

Abstract:

A simplified and efficient technique to correct Skeletal II's and/or short lower facial height is presented. This is a fixed technique that can achieve, in certain cases, similar result as a Bionator. This technique is called Fix-a-Nator[®]. The advantages of fixed over removable appliance are¹ forces are continuous, and² better patient compliance. Disadvantage is that it may not be effective in some patients with lateral tongue thrusts which may prevent eruption of posterior teeth.

Major components of the Fix-a-Nator Technique

There may have been others who have described this technique similar to the Fix-a-Nator; however, very little literature, if any, on this topic exists. At present, there appears to be no name attached to it. This author proposes to call this technique Fix-a-Nator[®]. This is a fixed functional technique that can increase lower facial height and/or reposition the mandible forward in the treatment of Skeletal II malpositions. Since it is a fixed technique, it is ideal for non-compliant patients. Additionally, the treatment is continuous since it is non removable.

The major component of this technique is some form of upper anterior guide slope, in this case the Bite Guide[®] by Ortho Organizer, and bilateral posterior composite molar buildups usually on the lower second molars. See figure 1.

Any straightwire brackets can be used with this technique. However, it is necessary that all posterior teeth have hooks attached to the brackets to allow up and down vertical elastics to hook over them. This author strongly recommends using CarriereLX[™] Self-Ligating, Frictionless brackets. Most self-ligating, frictionless brackets allow the archwires to slide through the brackets with minimal friction. Additionally, research has shown that light force will move teeth faster than heavy force. This combination of reduced friction and light force allows treatment time to be shortened by approximately 40%. However, the CarriereLX[™] has features that make it superior to other self-ligating brackets.

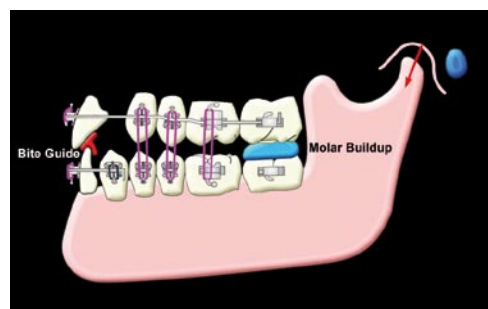


Figure 1. Showing Anterior guide slope (bite guide) and 2nd Molar composite buildup.

Advantages of the CarriereLX[™] Bracket

As illustrated in Figure 2, there are features that make the CarriereLX[™] superior to other self-ligating brackets:

1. Thinner profile and smooth labial surface of the locking mechanism for ultimate patient comfort.
2. Hooks available on 3's, 4's, and 5's, requirement for the Fix-a-Nator technique.
3. Dual-lock fasteners in the bracket face for more consistent closure and less accidental opening during mastication.
4. Simple locking mechanism. Can open and close with any pointed instruments including explorers. Also, the recessed dot used to open the cap is always on the occlusal. This helps doctors to easily orientate the brackets when bonding whether it is the upper brackets or the lower brackets. It is less confusing, and there is less chance of bonding brackets upside down.
5. Cap opens to the incisal/occlusal. Some self-ligating brackets open towards the gingival. The problem with this is that sometimes the sharp instrument may slip off the dot and poke patients in the gingival area. Also, during mastication, those caps that close toward the gingival are more easily dislodged and opened.
6. Mesial and distal portion of the wire slots have been rounded and smoothed to further reduce friction and enhance sliding mechanism. Some other brands of frictionless

Disclosure: The author developed the pre-formed anterior bonded guide slope, Bite Guide[®], manufactured by Ortho Organizers. Any royalty from this product is donated to the UMDNJ Phoenix Endowed Scholarship Fund for the financially disadvantaged dental students. This author would like to acknowledge OrthoOrganizers assistants with graphics and illustrations for this article.

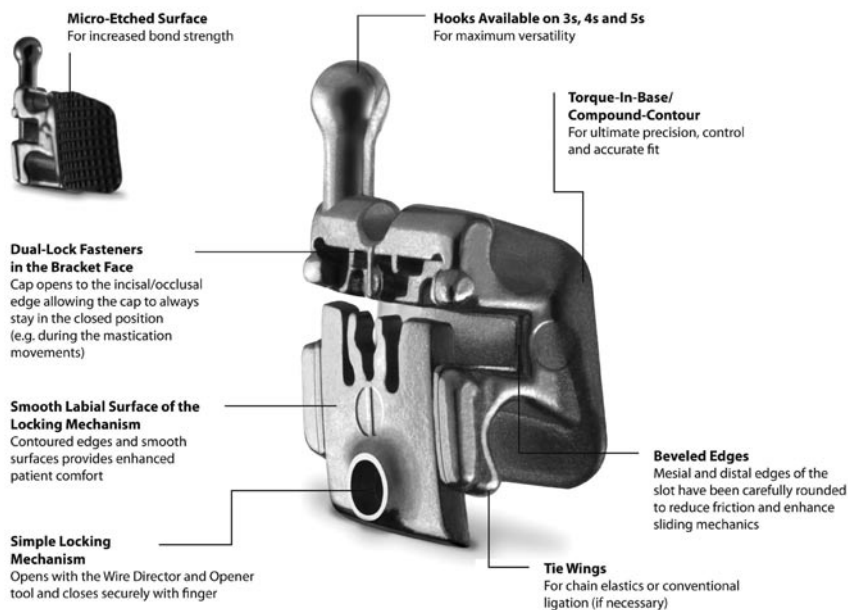


Figure 2. Advantages of the CarrierLX™ Self-Ligating, Frictionless bracket.

brackets have sharp edges in these areas. In severely rotated teeth, the wires may bind and rub against this edge. This causes friction, can cause wires to crimp, and at times can cause these wires to break.

7. Tie wings are more pronounced than other brands. This is important if for any reason, elastic or wire ligatures tied are needed to cinch the bracket onto the archwire. For example, you may initially need to cinch a severely rotated and misaligned tooth onto the wire with an elastic ligature tie. Once the tooth is better aligned, then it is easier to line up the wire to the bracket and easier to close the cap.

Anterior Guide Slope/Bite Guide

Fixed anterior guide slopes can be provided in various ways. One way is by using a lab processed appliance called the Rick-a-Nator.^{1,2,3} See figure 2a and 2b.

Various companies make bite buttons that bond to the lingual surfaces of upper centrals made either out of metal or composite materials. Other clinicians have described molding and light curing composites on the lingual surfaces of the upper centrals. The lower centrals rest on these buttons and they are useful in deep bite cases in preventing lower brackets from shearing off and/or preventing upper incisors from occluding traumatically to the lower brackets with the possibility of small incisal fractures.

The preferred preformed anterior guide slope by this author is the Bite

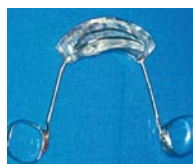

Figure 2a. Rick-A-Nator

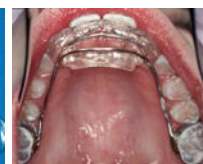

Figure 2b. Rick-A-Nator inserted



Figure 3a. Metal Bite Guide.



Figure 3b. Composite Bite Guide.

Guide[®] manufactured by Ortho Organizers, Inc.* It is especially developed for ease of placement and removal. It is designed for patient comfort and is made either in metal or composite material. See figure 3a & 3b. More importantly in TMD patients, it positions the mandible in a more neuromuscular position, which may often alleviate TMD and enhance facial esthetics and profile. This author defines neuromuscular position as repositioning the mandible and the TM joints down and/or forward away from the glenoid fossa to a more healthy joint position.

Many practitioners ascribe to Gelb^{4/7} TM joint position as being optimal especially in the treatment of TMD.^{4,5,6} Gelb^{4/7} is more in line with neuromuscular position than centric relations. This author defines centric relation as repositioning the mandible and the TM joints closer to the glenoid fossa. Over the years, the exact defini-

tion of “centric relation” appears to change. Rinchuse & Kandasamy states that “centric relation has been a controversial subject in dentistry for more than a century...The definition of CR has changed over the past half-century from retruded, posterior and, for the most part, superior condyle position to an anterior-superior condyle position.”⁷ Shanahan used the term “physiologic vertical dimension” based on using the phonetic test as being superior to centric relation.⁸

The phonetic bite tends to bring the mandible down and/or forward. Finally, Campos, Nathanson, and Rose used the term “physiologic centric relation” based on the swallow bite registration. They preferred this position over that of centric relations stating that it was more physiologic than mechanical.⁹ Again, the swallow bite registration tended to bring the mandible down and/or forward similar to neuromuscular position. This author’s position is that repositioning patients to centric relations may be fine only in a healthy stomatognathic system. If the TM joints are compromised and show degeneration, then neuromuscular position may be indicated. This view is also shared by Steenks, The, and Aaftink¹⁰

There are other bite buttons by other manufacturers designed in such a way as to treat to centric relations. These guide slopes tend to slide the mandible back and up which can compress the TM joints. See figure 4a. In most cases, this is contra-indicated especially with patients who have TMD and compressed TM joints.¹¹ Even with patients who have healthy TM joints, moving the mandible up and back may cause joint compression and possible joint pathology.

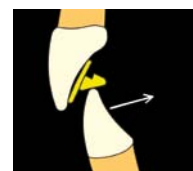


Figure 4a. Bite button causing mandible to push mandible back and up, centric relations.




Fig. 4b. Bite Guide keeps mandible down and forward, neuromuscular position.

The significant advantage of the Bite Guide is that it treats patients more to the neuromuscular position, which will bring the mandible down and forward. See Figure 4b. Most patients with deep bites and/or short

face syndrome tend to have headaches and other TMD symptoms.^{12,13,14,15} It is advisable to treat these patients to the neuromuscular position which often will decompress the TM joints similar to an orthotic appliance. Studies show that orthotics that decompress TMJ joints can often be beneficial for patients with temporomandibular disorders.^{16,17,18,19} See Figures 5a, 5b, and 5c.

The genesis of developing the Bite Guide was the Rick-A-Nator.³ However, the disadvantages of the Rick-a-Nator was that it was more involved, usually fabricated by an orthodontic laboratory, higher cost, and there was a waiting period. The advantage of the Rick-A-Nator is that it can treat cases with overjets greater than 4 mm. On the other hand, preformed guide slopes that can be bonded lingual to the upper centrals in which the lower central incisors could rest seemed to be an ideal solution to circumvent lab processing and time required for fabrication of a Rick-a-Nator, hence, the development of the Bite Guide.

The advantages of the Bite Guide over the Rick-a-Nator are that it can be placed at the time of appointment (no need for taking impressions and sending to laboratories), no delay time, less cost, also fixed, and it is hygienically better. The disadvantage

is that it can debond if patients chew hard food, or are hard bruxers, and it usually cannot be used in cases where the overjet is greater than 4mm. However, for overjets greater than 4mm, Bite Guides can be used as a base and composites can be added onto it to extend the ramp effect. In excessive overjet cases, posterior molar buildups are placed usually on the lower left and right second molars and incline planes are built onto the occlusion so as the patient closes, the inclined planes cause the mandible to slide forward onto the Bite Guide and help to position the mandible to its proper A-P and height position.

It is crucial to emphasize that if vertical elastics are used to actively erupt posterior teeth, that composite molar buildups are placed usually on the lower left and right second molars to provide a tripod occlusal support. Without this support, there is the potential of tipping the palatal plane down posteriorly. Cephalometrically, the palatal plane should ideally run posteriorly between the tip of the Greater Wing of Sphenoid and the Odontoid Process. Without posterior composite molar buildups for support, the force of the vertical elastics may cause the palatal plane to tip down and run through the odontoid process. See figure 6a and 6b.

Another potential problem is that the vertical elastics may force the posterior portion of the mandible to be pulled upward. This may force the TM joint to compress into the glenoid fossa superiorly and may potentially cause temporomandibular disorder.²⁰ See figure 7.

Indications:

1. Deep bite cases in mixed dentition. Do not use posterior molar buildups and vertical elastics in mixed-dentition. Works well with utility archwire technique.
2. Deep bite and/or short lower facial height cases in permanent dentition. Can use composite molar buildups on 2nd molars and vertical elastics to speed up eruption.
3. Skeletal II cases where the overjet is no greater than 4 mm (unless composites are added to the Bite Guides).

Contraindications:

1. Skeletal II cases where the overjet is greater than 4mm unless composites are added to the Bite Guides.
2. When patients lower incisors continue to bite behind the preformed anterior bite plane (if patient is unable to rest on the bite guide normally, discontinue this technique)
3. When there are no improvements with the Fix-a-Nator technique after 3 months
4. Poor oral hygiene

Precautions:

1. If one or both bite guides debond, attempt to get patient in as soon as possible to replace dislodged bite guide(s). Too much force may be exerted on a single lower central if only one bite guide is resting on it without the support of the other lower central supporting force on the other Bite Guide. There is also greater chance for lower incisal wear and small incisal fracture.
2. Minimally, there must at least be a segmented archwire from canine to canine in upper and lower arches when using bite guides.
3. Inform patients that although rare, there is a possibility that the bite guide may loosen and there may be possibility of swallowing or aspirating. (note, I have been using bonded anterior guides for over 12 years, and this has never happened).

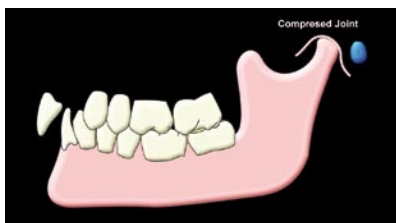


Figure 5a. Joint compression in TMD.

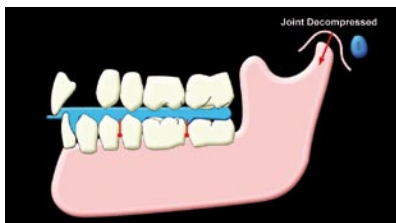


Figure 5b. Joint decompressed with Mandibular orthotic appliance.

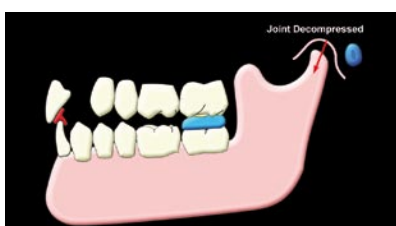


Figure 5c. Joint decompressed with Bite Guide and molar buildup.

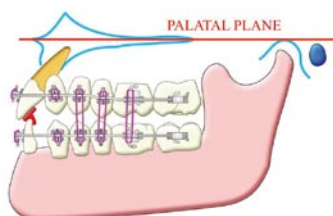


Figure 6a. Normal palatal plane.

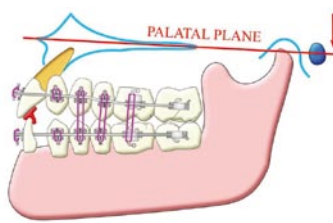


Figure 6b. Without posterior molar buildups for support, the palatal plane is tipped downwards.

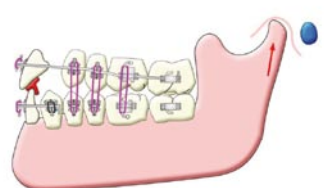


Figure 7. Without composite molar buildups, vertical elastics may force mandible up and cause compressed TM joints.

4. Inform patients that there may be some possibility of slight wear or small fracture of the top edge of lower central incisors. (note, I have used this technique to treat TMD patients quite successfully; however, heavy bruxers tend to debond Bite Guides more frequently and may cause some incisal wear on the lower incisors. This may be alleviated with molar buildups on the second molars).
5. In rare cases, the posterior teeth may not erupt into occlusion. This usually occurs with patients who have lateral tongue thrust. If this is found to be the case, you may consider discontinuing this technique.
6. Always use posterior molar buildups when actively erupting posterior teeth with vertical elastics.
7. Once vertical is established, start to reduce molar buildups in increments; for example 1/3 reduction each month for 3 months. It is advised to use colored composites, for example, blue to visually see composites upon removal.
8. Examine linguals of centrals with bonded Bite Guides regularly to insure there is no decay. Especially important when composites are added to the Bite Guides.

The Fix-a-Nator technique allows the practitioner to only super-erupt the upper posterior teeth (termed Fix-a-Nator U), only the lower posterior teeth (termed Fix-a-Nator L), or erupt both upper and lower posterior teeth simultaneously (termed Fix-a-Nator B). If eruption of only the upper posterior teeth is desired, then a heavy lower rectangular wire should be tied to all brackets on the lower teeth for anchorage. The upper teeth will have a segmented archwire from canine to canine. When vertical elastics are placed on the upper posterior teeth, there is a tendency for those teeth to super erupt more than the lower posterior teeth that is fixated to the heavy rectangular wire. See figure 8.

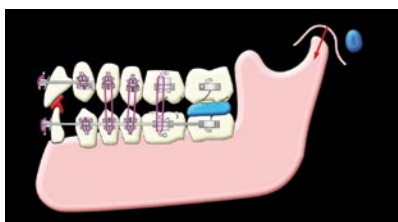


Figure 8. Showing technique to super erupt upper posterior teeth—Fix-A-Nator U.

If eruption of the lower posterior teeth is desired, then a heavy upper

rectangular wire is placed and tied to all the upper teeth. The lower teeth will have a segmented archwire from canine to canine. See figure 9.

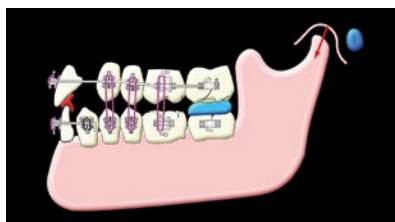


Figure 9. Showing technique to super erupt lower posterior Teeth—Fix-a-Nator L.

If eruption of both upper and lower posterior teeth is desired, Fix-a-Nator B, then segmented archwire should be tied to both upper and lower anterior teeth from canine to canine. There are no wires tied to both the upper and lower posterior teeth. See figure 10.

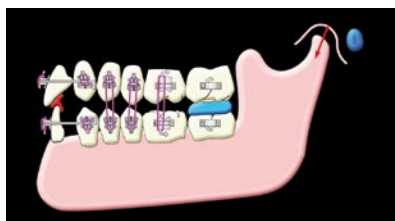


Figure 10. Showing technique to super erupt both upper and lower posterior teeth—Fix-a-Nator B.

With each particular patients, the practitioner must decide whether to use Fix-a-Nator U to erupt only upper posterior teeth, Fix-a-Nator L to only erupt lower posterior teeth, or Fix-a-Nator B to erupt both the upper and lower posterior teeth. One way, but not necessarily the only way, is to look at the patient's smile line. If the patient shows very little upper incisal edge and has a short smile line, then it may be advisable to super erupt only the upper posterior teeth. If the patient shows too much incisal edge when smiling or a tendency toward a "gummy" smile, then it may be advisable to super erupt only the lower posterior teeth. If patient has fairly even smile line, then there might be a tendency to super erupt both the upper and lower posterior teeth simultaneously as this technique tend to be faster and more efficient. However, note that a patient may have fairly even smile line, but may have a deep curve of Spee. In this situation, it may be better to super erupt lower posterior teeth only.

Bite Guide Bonding Technique

Bonding the Bite Guides is similar to bonding orthodontic brackets. This

author prefers using Fuji Ortho L (dual cured).** It has fluoride which inhibits decay and decalcification; it can be used on a slightly wet field, but more important, the bonding material can be mixed to a thick enough consistency so that the Bite Guide can be tacked onto the lingual surfaces of the upper centrals and it will stay in position prior to light cure. The bonding technique is as follows, see Figures 11 to 15:

1. Prophyl the lingual surface with pumice, figure 11.
2. Etch the lingual surface with the Fuji conditioner, figure 12.
3. Place Fuji material onto bond side of the Bite Guide, figure 13.
4. Tack Bite Guide onto lingual surface, with the bonding plate edge half a millimeter from the incisal edge and light cure, figure 14.
5. Tack on the second Bite Guide and allow the patient to bite onto the first Bite Guide to insure that the bite level of the second Bite Guides is even with the first Bite Guide. Then light cure, and both Bite Guides should be biting fairly even, figure 15. If slightly uneven, you may do some minimal adjustments with a diamond bur.

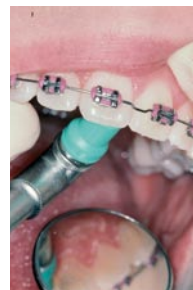

Figure 11. Pumice

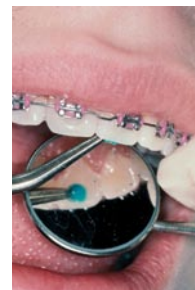

Figure 12. Etch

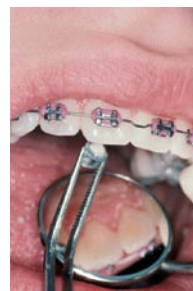


Figure 13. Bond

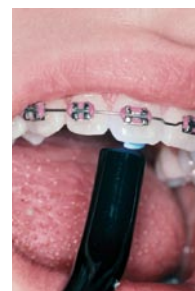

Figure 14. Light cure

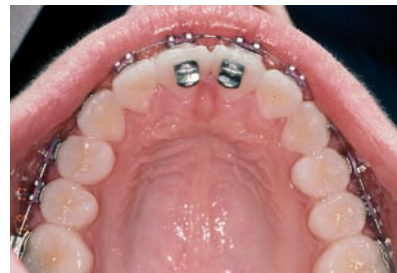

Figure 15. Bite Guide placement

Case Presentation

Male, pretreatment 4-10-2006, age 17y-4m. See Figure 16. Patient was referred to my office by Donated Dental Service (DDS) program. In this program, dentists volunteer to provide dental services to patients at no charge due to their economic situation. My only responsibility for this program was to provide examination, radiographs, cleaning and restorative treatment. This was done; however, as can be seen in Figures 17, 18 and 19, he was in need of orthodontic treatment. I offered to provide this treatment at no charge as long as his mother guaranteed that he would show up for every scheduled appointments, and if she would give me full permission to use his photographs and records for lectures, articles, marketing, and teaching purposes. She readily agreed.

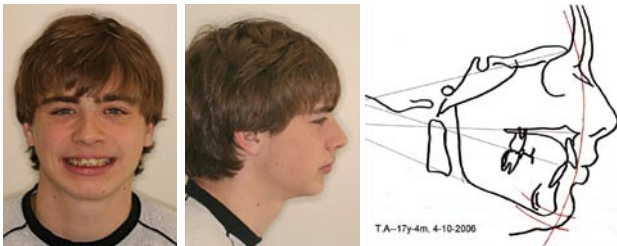


Figure 16. Pretreatment facial photos, and pretreatment ceph tracing, 17y-4m, 4-10-2006

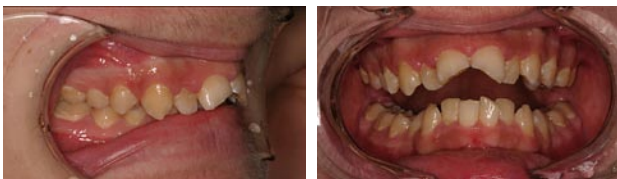

Figure 17. Pretreatment intra-oral photographs, 17y-4m, 4-10-2006. Note severe overjet and deep bite.

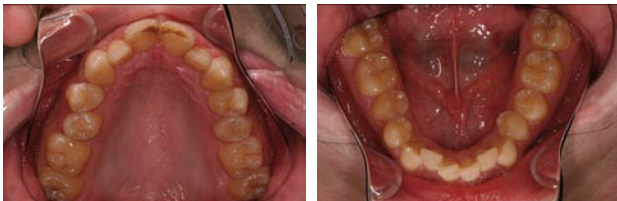


Figure 18. Pretreatment occlusal view of upper and lower arch, 17y-4m, 4-10-2006.

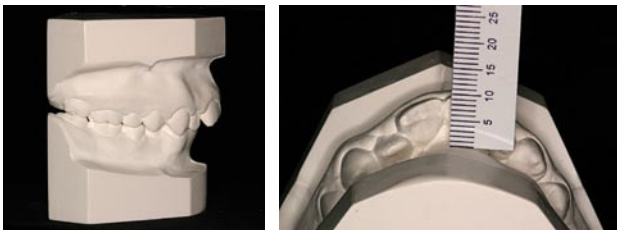


Figure 19. Pretreatment study models showing deep bite, and overjet of approximately 8 to 10 mm.

Carriere brackets were bonded and Bio-Kinetix thermally activated .014 preformed archwires were placed on both arches on 6-5-2006. See Figure 20 and 21. No Bite Guides were placed at this time. Note lower anterior crowding. It must be noted that this was my first orthodontic patient using the Carriere bracket.

Transitional photos were taken two months later on 8-14-2006 before the next archwires were placed. Note that the brackets and light .014 archwires alone expanded the

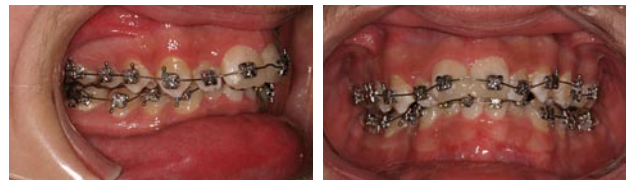


Figure 20. Intra-oral photos initial placement of Carriere Brackets and Kinetic .014 archwire, 6-5-2006.

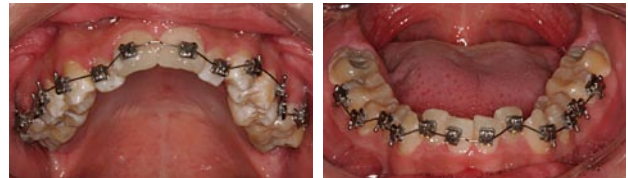


Figure 21. Upper and lower occlusal view. No Bite Guides at this time. Note lower anterior crowding.

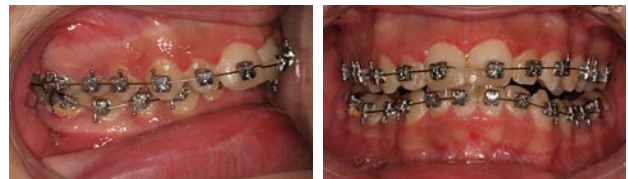

Figure 22. Transitional photos 2 months after the initial placement of Carriere brackets and archwires.

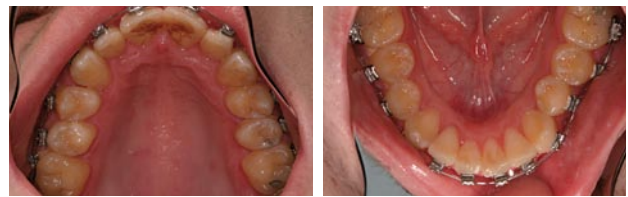

Figure 23. Note expansion and significant alignment of both arches with just .014 archwires.

upper and lower arch in just two months. Also, note significant improvement of lower anterior teeth in such a short time period. See Figure 22 and 23. At this visit, no wires were changed.

On 9-8-2006, .016 x .025 Bio-Kinetix archwires were placed on upper and lower arches. On 10-16-2006, Bite Guides were bonded lingual of nos. 8 and 9. See Figure 24 and 25. From 10-16-2006 to 1-11-2007, patient missed all his scheduled appointments

Patient finally was seen on 10-16-2007, and was firmly told that he must make all his appointments. Additionally, his oral hygiene was poor, and he was constantly reminded to maintain better oral hygiene. The wire was changed to .018 x .025 Bio-Kinetix archwires. After several appointments, it

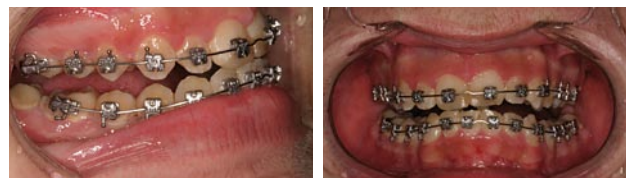

Figure 24. Bite Guides bonded lingual of nos. 8 & 9, on 10-16-2006.

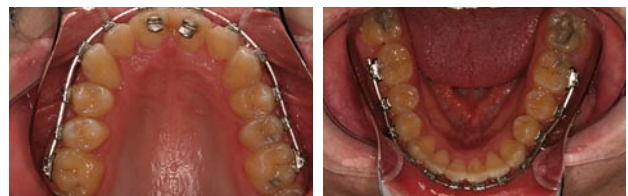


Figure 25. Occlusal views of upper and lower arch. Bite Guides on 8 & 9.

was clear that the patient's overjet was too excessive, and that his mandible was biting behind the Bite Guide, thus nullifying the anterior repositioning effect of the Bite Guide. On 3-19-2007, composites were bonded over the Bite Guides to extend the ramp effect. It was extended as far as necessary to prevent the patient from biting behind it. Composite molar buildups were placed on both left and right second lower molars. See Figure 26 and 27.

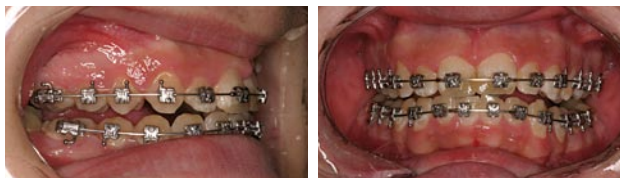

Figure 26. Wire changed to .018 x .025 Bio-Kinetix archwires on 3-19-2007.

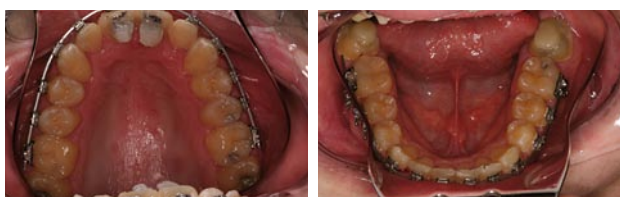

Figure 27. Composites bonded on top of Bite Guides to extend ramp.

From period 5-8-2007 to 5-15-2008, patient missed six scheduled appointments. During that time, patient was instructed to wear vertical elastics from canines to first molars. Initial elastics were 1/8 light, and then to 1/8 medium. Once posterior teeth were in occlusion, fixed appliances were removed. This was done on 5-15-2008. Figures 28, 29, and 30 show the facial and intra-oral photographs at the time the brackets and archwires were removed. Although significant improvements were made both facially and dentally, occlusion on the left side was not ideal due to poor patient cooperation.

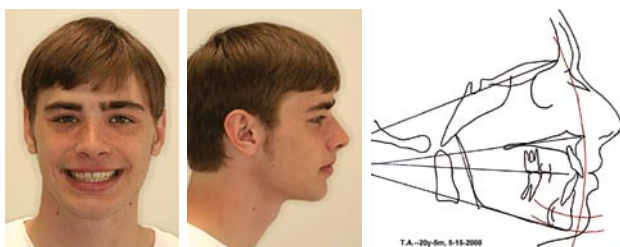


Figure 28. Post treatment facial photographs, and post treatment ceph, age 20y-3m, 5-15-2008.

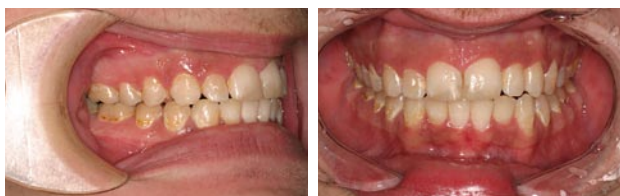

Figure 29. Post treatment intra-oral photographs, age 20y-3m, 5-15-2008.

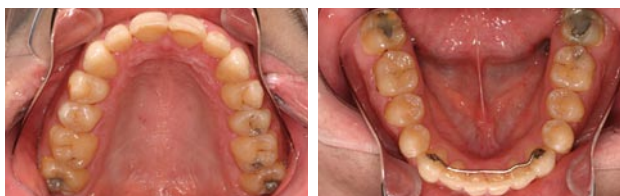

Figure 30. Post treatment occlusal view of upper and lower arch, age 20y-3m, 5-15-2008

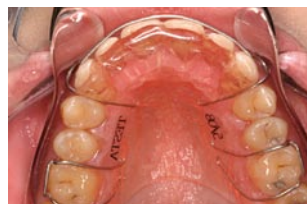

Figure 31. Maxillary anterior Hawley with anterior bite plane.

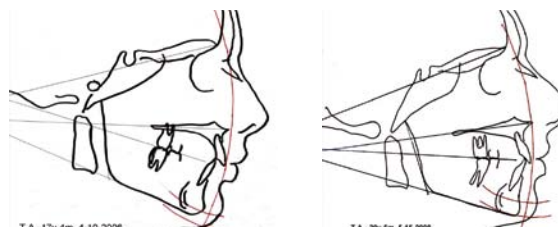


Figure 32. Side by side comparison of pretreatment ceph and post treatment ceph.

Fix-a-Nator technique was successful in repositioning the mandible more forward and increase lower vertical height. To minimize relapse, a maxillary Hawley retainer with an anterior bite plane was inserted. The instruction was to wear this retainer day and night for one year, and then to wear at night during sleep thereafter. See Figure 31.

Figure 32 shows side by side comparison of the pretreatment and post treatment cephalometric tracing of this patient using the Jefferson Cephalometric Analysis.21

Both the patient and his mother, who was a single parent, were happy with the treatment result. Figure 33 are studio photographs of this patient taken at my office on 6-11-2008.



Figure 33. Fix-a-Nator treatment made significant improvement in facial and dental esthetics. Studio photographs taken on 6-11-2008.

References

- * Ortho Organizers Pty Ltd, PO Box 478 Sylvania Southgate NSW 2224. Tel 1800 645 813.
- ** Fuji Ortho L by GC America, Inc. 3737 W 127th St, Alsip, IL 80803. Tel 800-323-7063.

For a complete list of references, please contact [Australasian Dentist gapmagazines@optusnet.com.au](mailto:gapmagazines@optusnet.com.au)

Two Day Seminar
 Friday 18th and Saturday 19th September 2009
 Sydney

For a registration form please contact:
 Ortho Organizers Pty Ltd
 Phone: 1800 645 813
 Email: sales@orthoorganizers.com.au