
Congenitally absent maxillary lateral incisors. A case report illustrating the use of a Mesialslider and a customised lingual appliance

Stephan Pies,* Benedict Wilmes† and Sivabalan Vasudavan‡

Specialist Orthodontic Practice, Remscheid, Germany,* Orthodontic Department, Heinrich-Heine-University, Düsseldorf, Germany† and Specialist Orthodontic Practice, Perth, Australia; Senior Research Fellow, School of Anatomy, Faculty of Science, University of Western Australia, Perth, Australia; Visiting Lecturer, Department of Developmental Biology, Harvard School of Dental Medicine, Boston, USA‡

Background: A young adolescent female, aged 17 years and one month, presented seeking orthodontic treatment to address the congenital absence of her maxillary lateral incisors.

Aims: The therapeutic aims were to provide an adequate aesthetic and functional occlusion, coupled with sound adjunctive periodontal tissue relationships and a favourable long-term prognosis.

Methods: The malocclusion was managed by customised lingual orthodontic appliances and the adjunctive use of direct skeletal anchorage derived from two palatal mini-implants.

Results: The treatment objectives of good aesthetics, a functional occlusion, normal function, a healthy periodontium and a balanced profile were readily achieved. The retention records demonstrate the stability of the correction. The treatment duration was approximately 41 months, which encompassed the use of full fixed customised lingual appliances over a period of 24 months.

(Aust Orthod J 2018; 34: 103-116)

Received for publication: August 2017

Accepted: December 2017

Stephan Pies: praxis@kforemscheid.de; Benedict Wilmes: wilmes@med.uni-duesseldorf.de; Sivabalan Vasudavan: siva@post.harvard.edu

Introduction

The problem of absent permanent teeth generally has a genetic or an acquired aetiology, and may involve hypodontia of up to six missing teeth; oligodontia, more than six missing teeth; or complete anodontia, when all teeth are missing. The prevalence of congenitally missing lateral incisors varies from 1.5–11.5% and is therefore a commonly-presenting dentofacial anomaly.¹

Patients with congenitally missing teeth may benefit greatly from orthodontic treatment, in which the adjacent teeth are moved in a controlled manner to close the resulting spaces. Although implants, crowns, bridges, partial prostheses or fixed prostheses could be used to replace the missing teeth, orthodontic space

closure and substitution by canines, premolars, or the first, second and third permanent molars is also a viable option. In many cases, space closure to the mesial seems to be a favourable management goal, as treatment can be readily completed as soon as the eruption and development of the dentition is complete. This approach may prove to be a cost-effective option as the patient does not require subsequent prosthetic rehabilitation with fixed partial dentures or implants. Canine substitutions can be accomplished and achieve good aesthetic outcomes by tooth reshaping and positioning, bleaching or porcelain veneers.^{2,3}

Orthodontic space closure should be individually tailored and based on the diagnosis and treatment plan. The selection of treatment, involving any technique, stage, spring, or appliance design, should be based on

the desired tooth movement. Consideration of the force system produced by an orthodontic device aids in determining the utility of the device for correcting a specific problem. Anchorage may be defined as the amount of movement of the posterior teeth (molars, premolars) to close the extraction space in order to achieve selected treatment goals. Therefore, the anchorage needs of an individual treatment plan could vary from absolutely no permitted mesial movement of the molars/premolars (or even distal movement of the molars required) to complete space closure by protraction of the posterior teeth.

A complex biomechanical challenge exists in clinical scenarios when the successful protraction of all premolar and molar teeth is required without retraction of the anterior teeth. Loss of anchorage is a major orthodontic problem that often leads to compromised treatment results, not only in extraction cases, but also in cases requiring molar distalisation or protraction. Therefore predictable anchorage control is important in these circumstances because lingual tipping of the maxillary and the mandibular incisors is best avoided.

The use of skeletal anchorage is often indicated to assist in achieving the treatment objectives of protracting the maxillary posterior teeth and closing the space resulting from the maxillary lateral incisors agenesis. Skeletal anchorage can be derived from dental implants (osseointegrated dental analogues), surgical fixation wires, surgically-placed mini-plates or 'on-plants'. Skeletal anchorage support does not rely on patient compliance, permits the incorporation of often simple biomechanics, and provides more predictable, efficient and effective treatment options.

The judicious use of mini-implants has become a commonly-utilised adjunctive orthodontic treatment option due to their versatility in integration with concomitant biomechanical initiatives, minimal invasiveness, and relative cost effectiveness. To date, the alveolar process remains the most preferred insertion site,⁴⁻⁸ which can be in the path of moving teeth. However, due to varying bone and soft tissue conditions, orthodontists are still confronted with an average mini-implant loss rate of 16.1%.⁹⁻¹²

To enhance the retention success rate of a mini-implant, five strategies have been developed:

1. The selection of the optimum insertion site,
2. The avoidance of direct root contact by the mini-implant,

3. The placement of a mini-implant outside of the intended path of tooth movement,
4. The use of coupled tandem implants to raise mini-implant stability, and
5. The use of implants with sufficient dimension related to length and diameter.

The successful application of these strategies, and the choice of the anterior palate as a preferred insertion site, has resulted in a profound reduction in the loss of mini-implants to a rate of 2.1%.¹³ Hence, particularly in the maxilla, the anterior palatal area is advantageous since all teeth can be moved without interference from the mini-screws.¹⁴ Further advantages of the anterior palate are good bone quality, a thin attached mucosa, minimal risk of tooth injury, and a high associated success rate.^{15,16}

The opportunity for placement of a mini-implant in the region of the anterior palate has rendered the need for placement of the mini-implant within the alveolar ridge almost obsolete. Mini-implants have expanded the envelope of tooth movement widely. Based upon continued experience and the development of clinical acumen, coupled with robust scientific evaluation, innovative solutions for a variety of treatment objectives such as molar distalisation^{17,18} and mesialisation,¹⁹ molar intrusion,²⁰ extrusion of impacted teeth,²¹ midline correction,²² early Class III treatment²³ and anchorage of anterior and lateral dental segments²⁴ have been successfully developed.

The present case report describes the diagnosis, specific treatment objectives and the orthodontic management of an adolescent female patient, who presented at age 17 years and one month for the management of her malocclusion characterised by the congenital absence of the maxillary lateral incisors, unerupted and ectopic premolar teeth, and an anterior deep bite. The treatment objective was to close the residual space in the maxillary arch through the protraction of the maxillary canines, first and second premolars, and the first and second molars. The biomechanical plan consisted of utilising direct anchorage with two mini-implants inserted into the anterior hard palate and subsequent detailing of the occlusion with customised lingual full fixed orthodontic appliances (WIN, DW Lingual Systems GmbH, Bad Essen, Germany).

The results of the orthodontic treatment, retention phase and follow-up care demonstrate that good aesthetics, functional occlusion and stability were

achieved. There were no complications associated with the utilisation of the mini-implants.

Diagnosis and aetiology

A 17-years-one-month old adolescent female presented seeking orthodontic treatment to address her chief concern of congenitally missing upper lateral incisors and spacing in the posterior maxillary arch. The patient reported a history of previous orthodontic treatment in early adolescence, which consisted of mesialisation of the maxillary canines and space closure of a central diastema. The patient presented with a balanced facial profile, mildly reduced lower anterior facial height, and mild skeletal asymmetry with the chin deviated to the right of her mid-sagittal plane. Approximately 50% of the maxillary incisor crown height was visible on posed smiling, and the smile arc was non-consonant relative to the lower lip. The intraoral dental relationships included an increased anterior deep bite of 2.8 mm, a Class II incisor and canine relationship, and maxillary arch length excess (spacing) of 5.0 mm located between the maxillary right and left canines and the first premolars. Delayed and ectopic eruption of the maxillary left second premolar tooth was noted, with prolonged retention of the maxillary left primary second molar (Figure 1 and Figure 2). The maxillary dental midline was coincident with the facial midline, but the mandibular dental and skeletal midlines were both deviated to the right of the mid-sagittal plane by 2.0 mm. The pretreatment photographs and dental casts are shown in Figure 3 and Figure 4, respectively.

The initial panoramic radiograph reveals the congenital absence of the maxillary lateral incisors 12 and 22, and the previously protracted canines 13 and 23. The maxillary third molars were unerupted, and appeared to be disto-angularly impacted (Figure 5). The initial cephalometric analysis showed a moderate Class III sagittal discrepancy (ANB angle 0.9° , WITS -0.5 mm) with a hypodivergent vertical pattern (Figure 6, Table I).

A functional assessment of the occlusion did not show a discrepancy between centric occlusion and centric relation. There were no signs or symptoms of temporomandibular dysfunction and there were no other medical or dental concerns.

Treatment objectives

The clinical criteria for canine substitution of the congenitally absent maxillary lateral incisors include:

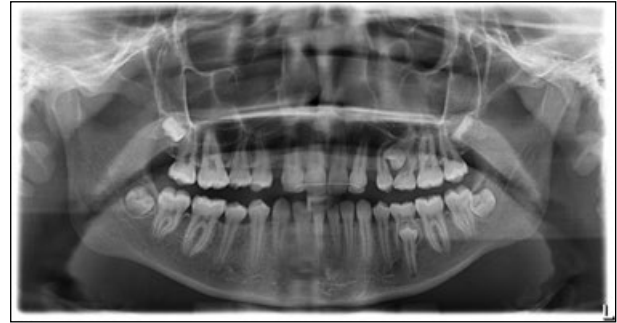

Figure 1. Panoramic radiograph at the age of 16.

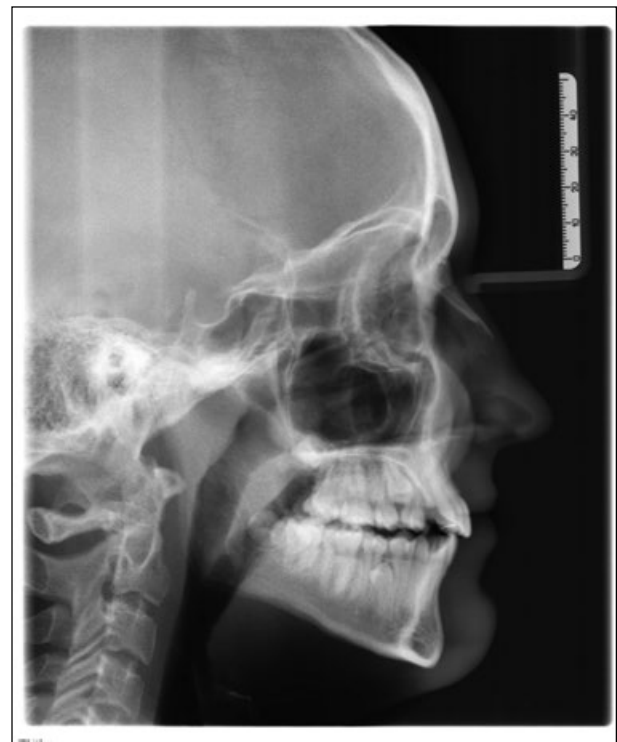

Figure 2. Lateral cephalogram at the age of 16.

- Ideally:
 - A Class II molar relationship.
 - Minimal crowding of the mandibular teeth.
 - An acceptable facial profile.
- Anterior tooth-size relationship:
 - Canines are substituted for lateral incisors and so a maxillary anterior tooth-size excess is created.
 - The widths of the maxillary six anterior teeth often must be reduced in size to create correct overbite and overjet relationships.
- Length, shape and colour of the maxillary canine crowns:

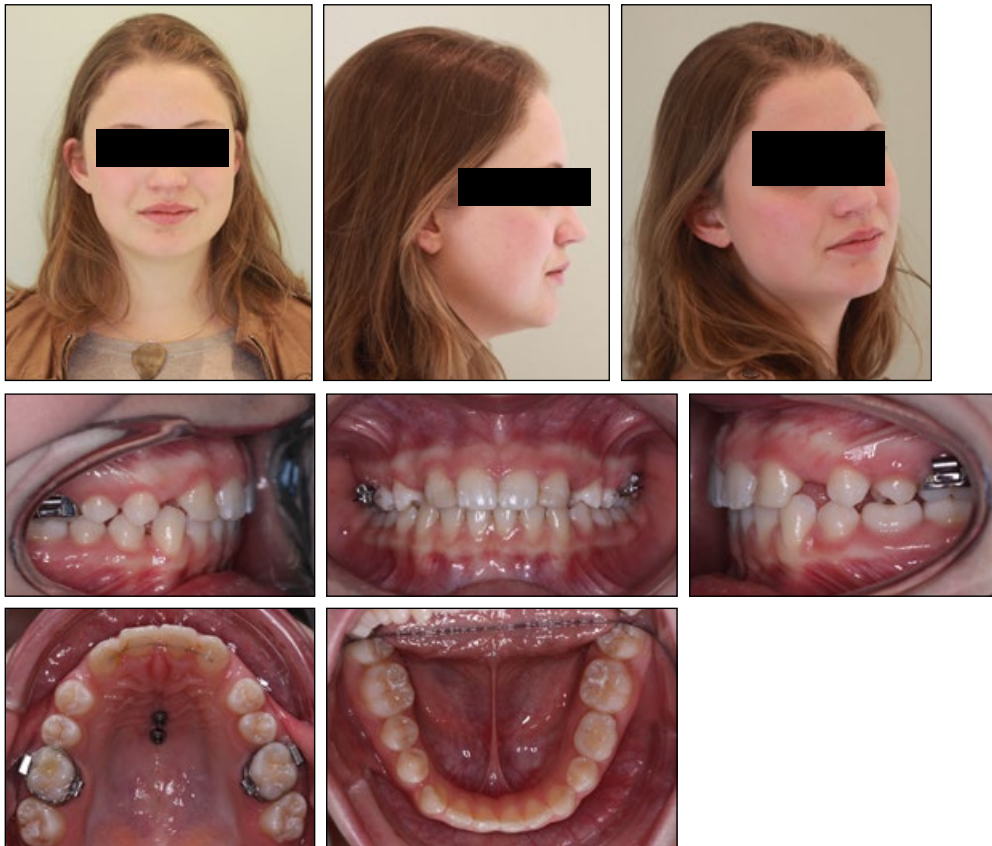

Figure 3. Facial and intraoral photographs at the beginning.

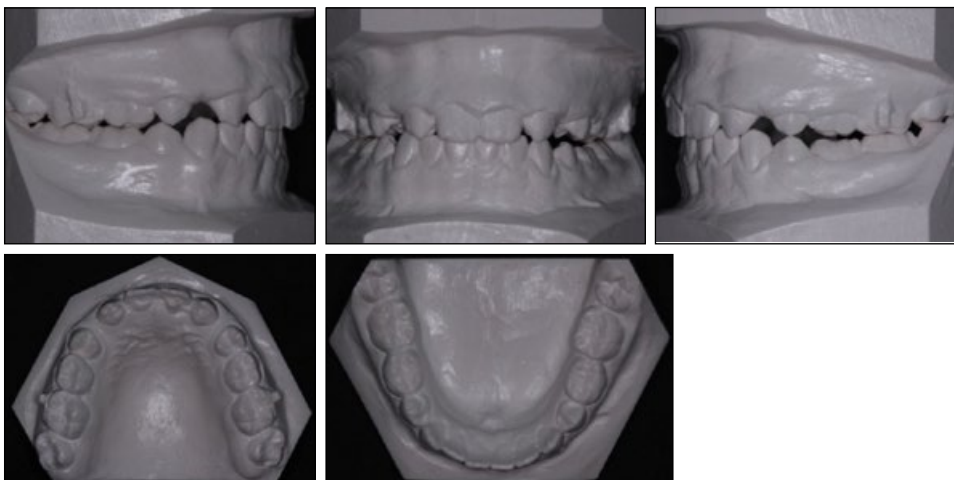


Figure 4. Photographs of pretreatment dental casts.

- Gingival margins must be positioned more incisally relative to the central incisors, because the crown lengths of the lateral incisors are typically shorter than the central incisors.
- The canines must be erupted, and their cusps equilibrated to create the illusion that they are lateral incisors.
- Labial contour, either convex or rounded,

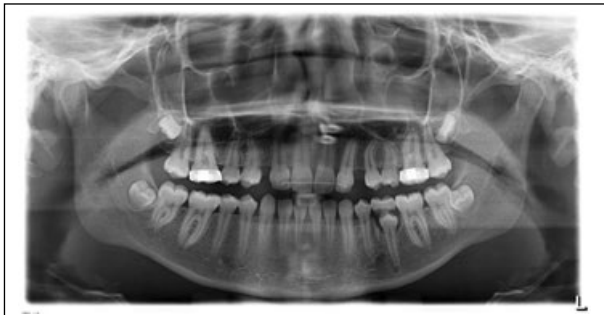requires restoration by a porcelain or composite veneer to create an acceptable aesthetic result.

Following the procurement of comprehensive orthodontic records, a problem list summarising the deviations of normal relationships of the craniofacial skeleton and dentition was compiled, along with the establishment of specific treatment objectives and the

Table 1. Changes in cephalometric variables before and after treatment.

Cephalometric variables	Before treatment	After treatment	Change
SNA (°)	81.2	80.1	-1.1
SNB (°)	79.6	79.1	-0.5
ANB (°)	1.6	1.0	-0.6
WITS (mm)	0.6	-2.3	-2.9
SN-PP (°)	5.1	4.9	-0.2
SN-MP (°)	29.6	28.5	-1.1
PP-MP (°)	24.5	23.5	-1.0
ArGoMe (°)	130	128	-2
Ui-PP (°)	110	111	1
Li-MP (°)	96.5	95.4	-1.1
Ui-Li (°)	129	130	1
OJ (mm)	2	2	
OB (mm)	2.8	2	-0.8

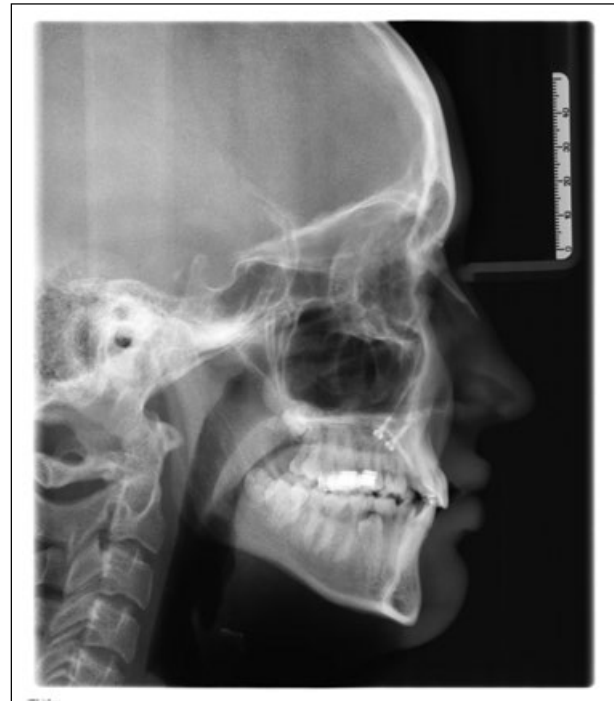SNA, Angle Sella-Nasion-A point; SNB, Angle Sella-Nasion-B point; ANB, Difference of SNB and SNA; WITS, Linear difference between B point and A point on functional occlusal plane; SN-PP, Angle Sella-Nasion line to Palatal plane; SN-MP, Angle Sella-Nasion line to Mandibular plane; PP-MP, Angle between Palatal and Mandibular planes; ArGoMe, Angle between Articulare-Gonion-Menton; Ui-PP, Angle between Upper incisor long axis and Palatal plane; Li-MP, Angle between Lower incisor long axis and Mandibular plane; Ui-Li, Angle between long axes of Upper and Lower incisor; OJ, Overjet; OB, Overbite.

**Figure 5.** Pretreatment panoramic radiograph.

development of an orthodontic biomechanical plan. The patient made an informed decision to proceed with a treatment program involving closure of the residual maxillary arch spacing through the advancement of the maxillary canines, first and second premolars, and the first and second molars.

The biomechanical system used for space closure should, according to Burstone,⁴³ fulfil the following requirements:

- The applied system should be able to perform, on request, type A, B or C anchorage.
- The system should require minimal patient cooperation. This implies that the use of intermaxillary elastics and extra-oral anchorage would be limited.
- The system should be able to control the axial inclination and rotation of the tooth and also arch width.

**Figure 6.** Pretreatment lateral cephalogram.

- The system should deliver a constant force system, producing tooth movement within bone by means of direct resorption.
- The system should be well accepted by the patient from a comfort and an aesthetic perspective.
- The system should be easy to use, robust and require few adjustments.

A key treatment objective was to maintain the antero-posterior position of the maxillary and mandibular incisors, to avoid potential undermining of the facial integument. Additionally, the patient sought correction of the midline discrepancy, and an improvement in the animated maxillary incisor tooth display. Secondary to the biomechanical complexities associated with space closure and to achieve the sagittal, transverse and vertical corrections needed, two mini-implants were inserted in the anterior of the hard palate.

Treatment alternatives

Alternative treatment strategies to address the congenital absence of the maxillary lateral incisors include removable and fixed prosthetic options, osseointegrated implants, and autotransplantation of the lower second premolar teeth. Whilst these prosthetic options may be associated with potentially reduced treatment times, each requires surgical intervention (dental implants, autotransplantation) and potentially significant tooth preparation (fixed prosthetics). Variable long-term survival rates and complications of the alternative prosthetic and surgical options have been reported.^{25,26} Additionally, coordinated surgical-orthodontic care may also be a consideration, with orthognathic surgery to improve facial vertical proportions and address the chin asymmetry.

Treatment progress

The treatment objectives consisted of Type C anchorage requirements, in which more than 75% of the residual space needed to be closed by the forward movement of the posterior segments through the mesialisation of the maxillary premolars and molars.

A Mesialslider (1.1 mm stainless steel wire) connected to two median palatal mini-implants (dimensions of 2 × 11 mm anterior and 2 × 9 mm posterior, PSM Benefit system), described and reported previously by Wilmes et al.,^{19,27-29} was planned for the upper arch as a source of direct anchorage.

Treatment commenced with the insertion of the two palatal mini-implants, under local anaesthesia, distal to the third palatal rugae. Stainless steel circumferential bands were cemented to the maxillary molars.

Subsequently, a Mesialslider appliance was fitted (Figure 7). There were no brackets bonded to the maxillary arch at this time. Custom fabricated 'Julisprings' (0.016 × 0.016 inch, Elgiloy) were attached to the maxillary first premolars, and directly onto the framework of the Mesialslider. The mesial displacement force was applied through the bilateral use of Nickel-Titanium open coil springs (240 g) supported by two Guerin locks that were attached to the Mesialslider. Therefore, all distalising forces were supported by the Mesialslider without application to the molars. The chosen biomechanical approach enabled the line of force action to be applied closer to the centre of resistance of the maxillary first premolars, thereby achieving space closure predominantly through translation, or bodily tooth movement. The maxillary right and left second premolars were connected to the maxillary molars with a sectional archwire (0.016 × 0.022 inch, stainless steel). The localised space between the maxillary central incisors, canines and first premolars was closed approximately six months into treatment (Figure 8).

The newly established position of the maxillary first premolars was stabilised by the placement of the Guerin locking mechanisms directly distal to the 'Julisprings'. The protraction of the connected upper second

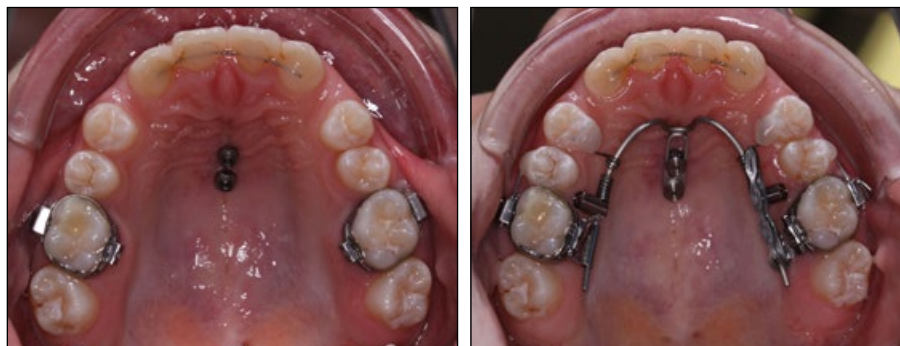

Figure 7. Occlusal view of the Mesialslider attached to two mini-implants at the start of maxillary premolar and molar mesialisation.

premolars and first molars of either side commenced with an elastomeric chain attached to the 'Julisprings' (0.016 × 0.016 inch Elgiloy). The Nickel-Titanium open coil springs were removed. The mesialisation of the combined second premolars and first molars was further assisted through the application of elastomeric powerchains attached to the 'Julisprings' (Figure 8). After 17 months of treatment, the mesialisation of the maxillary second premolars and the maxillary first and second molars was completed, and the Mesialslider was removed (Figure 9). During this time both upper first molars were mesialised 5.0 mm.

Polyvinyl siloxane impressions of the maxillary and mandibular arches were obtained for the fabrication of customised lingual full fixed orthodontic appliances (WIN, DW Lingual Systems, GmbH, Bad Essen, Germany). An interim Essix© clear removable retainer was provided to the patient to maintain space closure prior to the fitting of the lingual appliances.

The comprehensive phase of treatment included the underlying objectives of levelling and alignment of the

maxillary dental arches, along with the completion of space closure in the mandibular arch. The midlines still required correction and the maxillary anterior teeth were to be positioned for prosthetic recontouring (Figure 10 and Figure 11).

To facilitate prosthetic enhancement of the clinical crown height of the maxillary first premolars and better simulate the natural appearance of a maxillary canine, the maxillary first premolars were intruded through a series of 0.0175 × 0.0175 inch TMA customised archwires. The first finishing archwire was programmed to deliver an intrusive displacement of 1.0 mm, and the second archwire, a total intrusive displacement of 1.5 mm to the maxillary first premolars (Figure 12).

The comprehensive phase of treatment using the customised lingual appliances was completed over a period of 24 months. The appliances were removed, and a solid gold fixed lingual retainer (Ortho-FlexTech, Reliance Orthodontic Products, IL, USA)

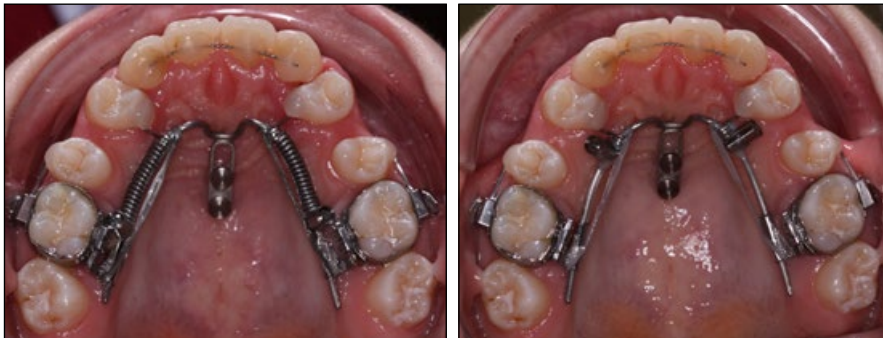


Figure 8. Midstage intraoral photographs recorded six months into treatment.

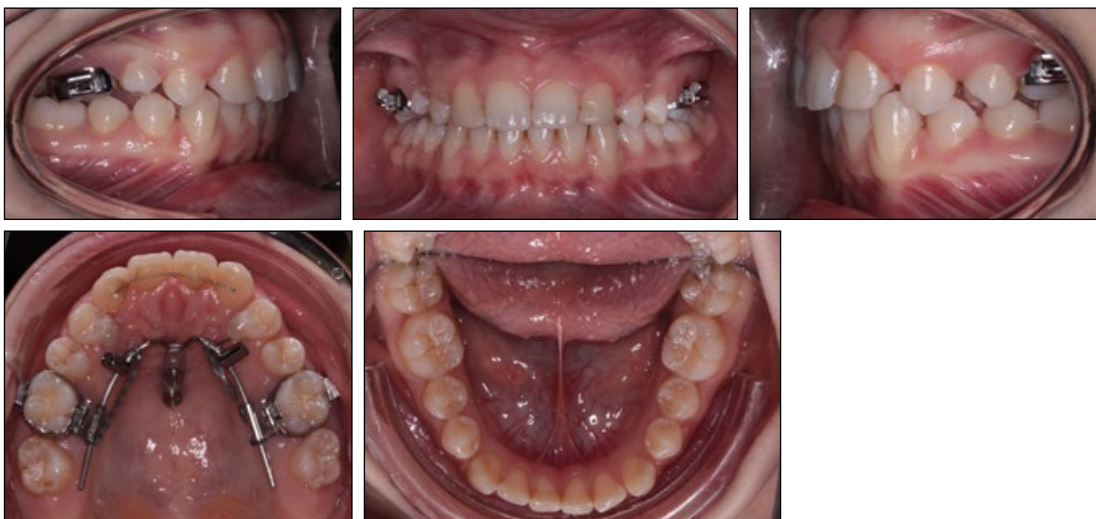

Figure 9. Progress intraoral photographs recorded 17 months into treatment highlighting the excellent mesialisation of all upper premolar and molar teeth.

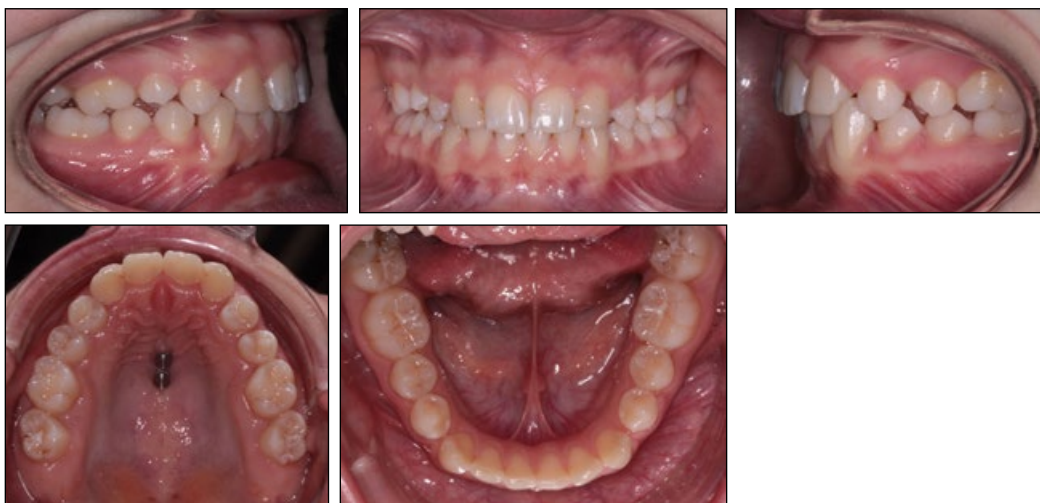

Figure 10. Intraoral photographs prior to insertion of the fully individualised lingual appliance (WIN®).

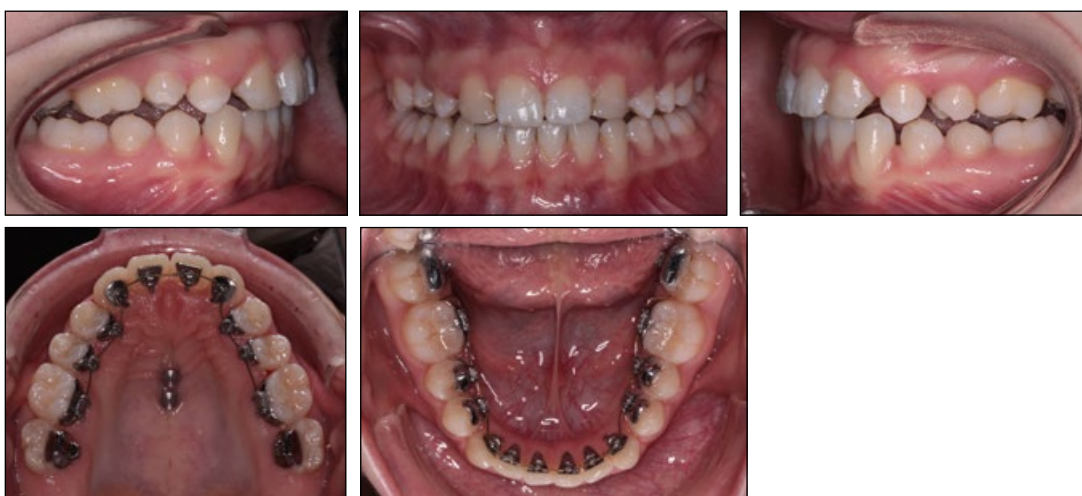

Figure 11. Intraoral photographs following insertion of the fully individualised lingual appliance (WIN®).

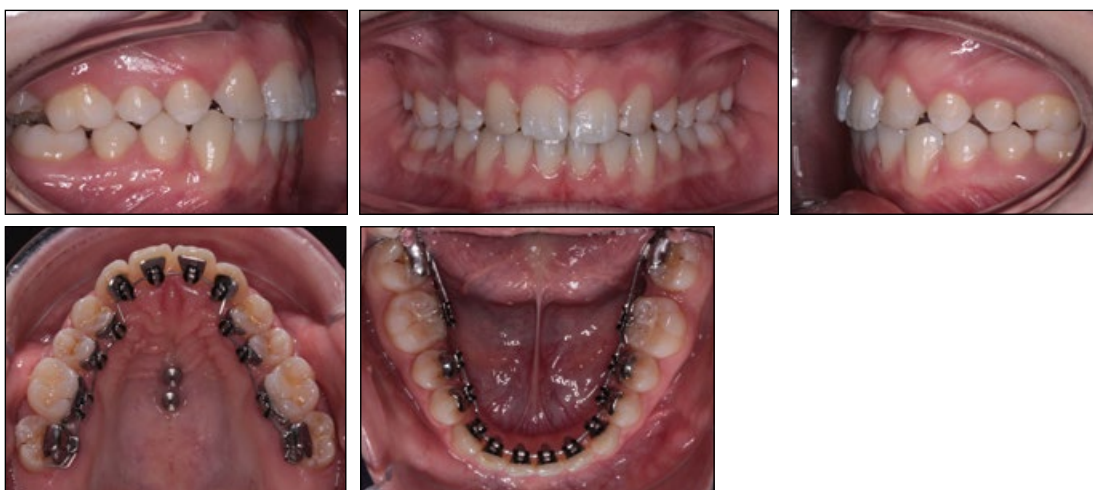

Figure 12. Intraoral photographs illustrating the intrusion steps of the 0.0175 × 0.0175 inch TMA wire to prepare for the later reshaping of the first premolar teeth.

was placed in the mandibular arch, and a maxillary Essix© clear removable retainer fitted. During the time of treatment, the overjet reduced from 2.5 to 2.0 mm and the overbite was reduced from 2.8 to 2.0 mm.

Treatment results

The planned treatment objectives were achieved during the programmed course of care. At the conclusion of active treatment, the mandibular and maxillary arches were well aligned with a therapeutic Class II canine relation, acceptable overbite and overjet relationships, and the establishment of coincidental dental midlines. The post-treatment photographs recording at the debonding appointment are illustrated in Figure 13, and corresponding dental models in Figure 14.

The panoramic radiograph taken at treatment completion (Figure 15) demonstrates bodily mesialisation of the premolar and molar teeth, and maintenance of sound alveolar bone levels. The lateral cephalogram (Figure 16, Table I) demonstrates sound skeletal sagittal and vertical balance with maintained incisor angulations and a bodily mesialisation of all upper premolars and molars. The patient was advised to continue using the maxillary removal retainer, and a post-retention review demonstrated sound stability of the dental movements performed (Figure 17 and Figure 18), including maintenance of the established anterior overbite relationship.

After two years of retention the patient exchanged her composite veneers for porcelain veneers (Figure 19).

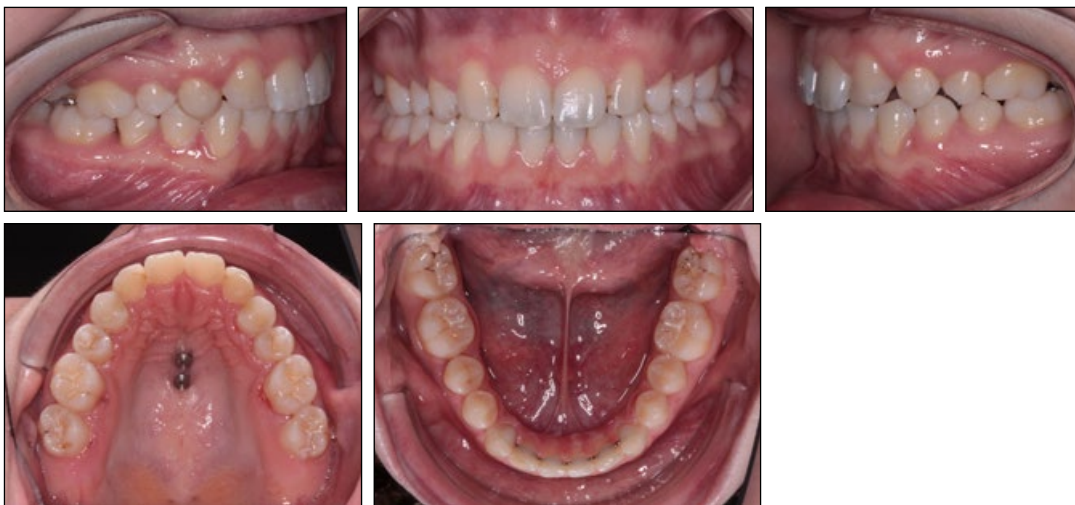

Figure 13. Intraoral photographs after debonding of the fully individualised lingual appliance (WIN®).

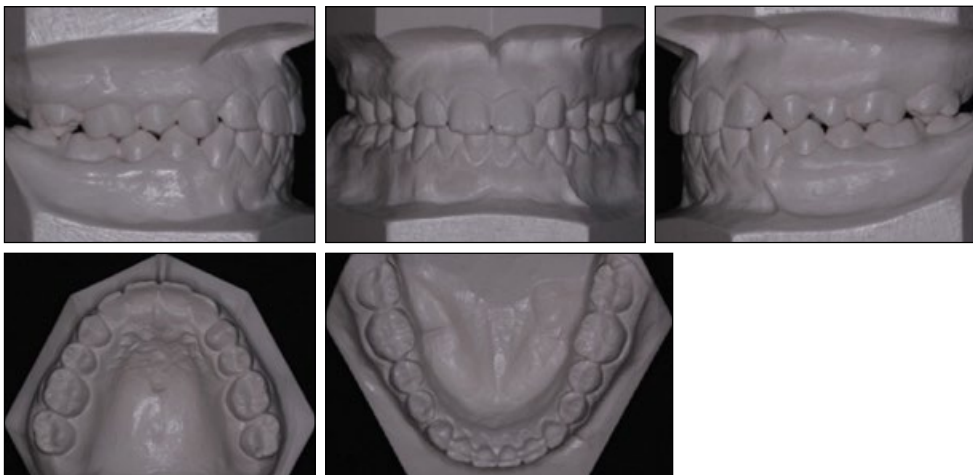

Figure 14. Photographs of dental casts after debonding of all appliances.

The patient has not reported any complications associated with the bonded fixed lingual retainer.

The pre- and post-treatment lateral cephalogram obtained at debond were superimposed on cranial base structures (Figure 20) to evaluate relative regional changes in the skeletal and dental areas (superimposed on Sella-Nasion line at Sella). The superimposition and measurements listed in Table I highlight the preservation of anterior anchorage, and bodily mesialisation of all upper premolars and molars. There were no other significant skeletal, dental or soft tissue changes observed.

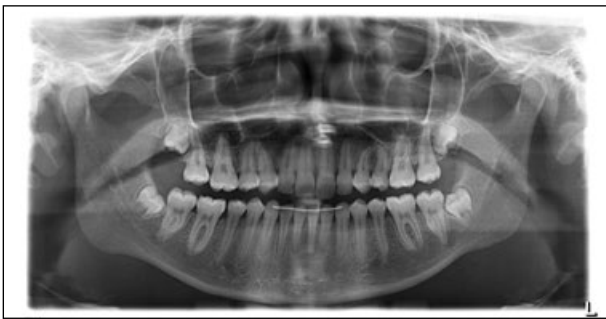

Figure 15. Panoramic radiograph following debonding and completion of active orthodontic treatment.

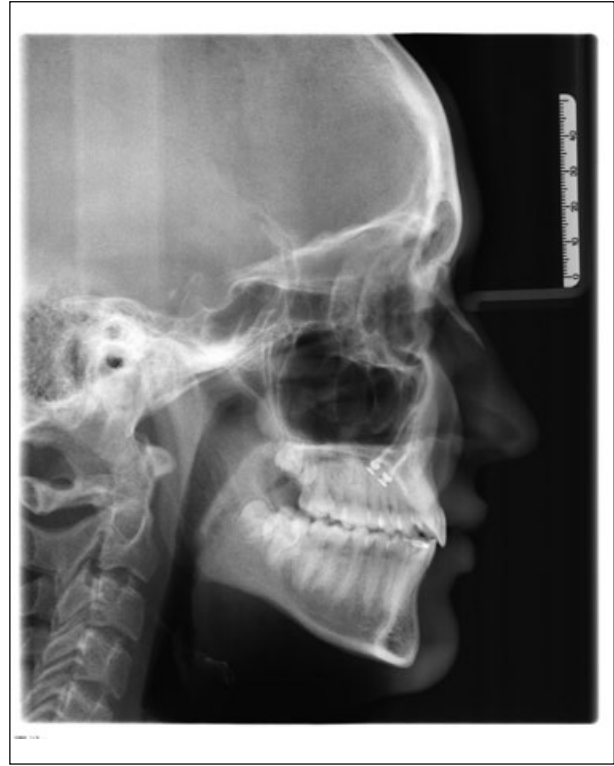

Figure 16. Lateral cephalogram immediately following debonding and completion of active orthodontic treatment.

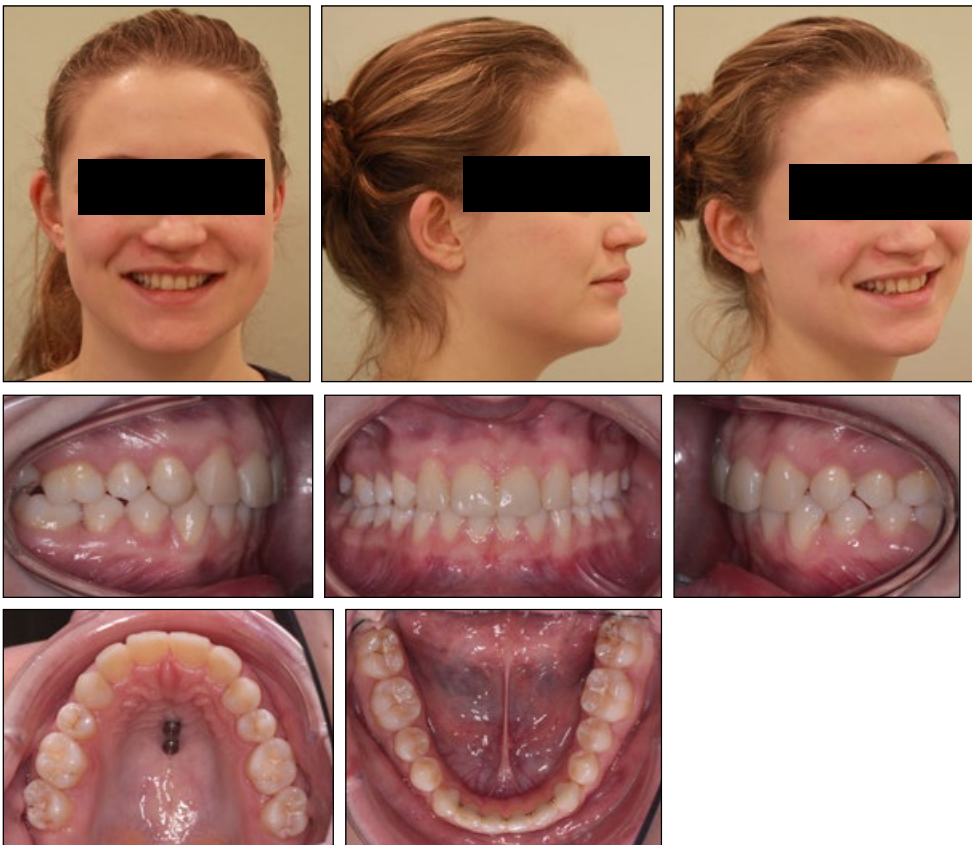

Figure 17. Facial and intraoral photographs after one year of retention.

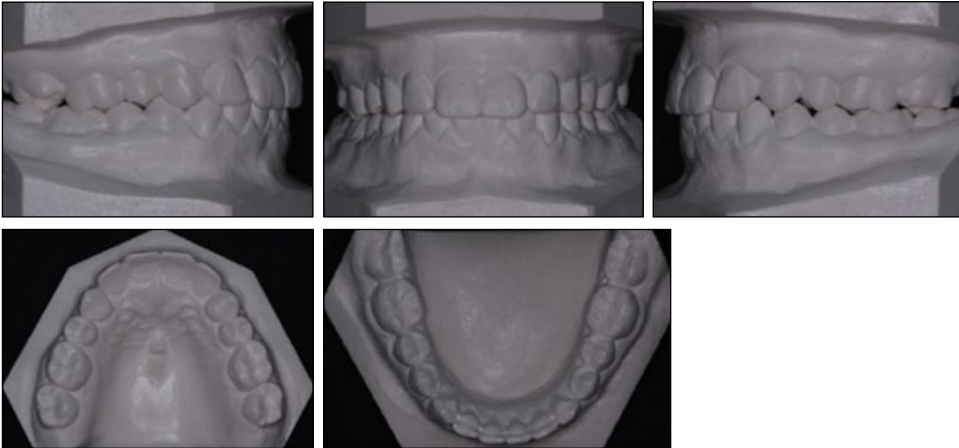


Figure 18. Photographs of dental casts after one year of retention.

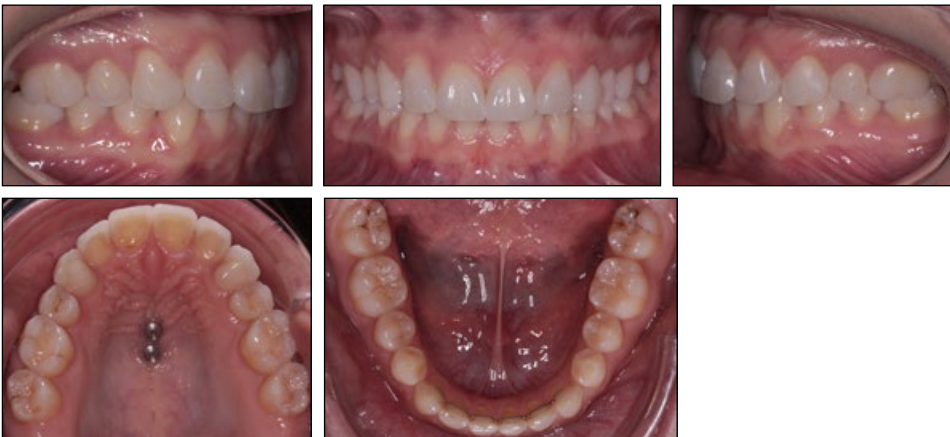

Figure 19. Intraoral photographs after two years of retention.

Discussion

There has been a recent proliferation of published cases and clinical studies illustrating the mesialisation of second and third molars into the space of missing first molars.^{19,30-35} However, it is believed that the orthodontic treatment performed for the present patient was unique amongst previously reported cases for several reasons. To ensure that no retraction of the maxillary anterior segment occurred during treatment, the requirement to reinforce anterior and vertical anchorage was imperative. Furthermore, the congenital absence of the maxillary lateral incisors created a scenario in which space closure in the maxillary arch had to be performed entirely through protraction of the maxillary posterior dental segment. Specifically, the first and second premolars and molars had to be advanced, requiring anchorage reinforcement. Finally, the maxillary and mandibular full fixed appliances were not attached during the first 17 months of active space closure in the maxillary

arch. Although the total treatment time was 41 months, the proportion of time spent in full fixed appliances was only 24 months. The extended period of full fixed appliance wear was due to the patient residing in Spain, and travelling to Germany on an intermittent basis for care. The comprehensive phase of treatment of the malocclusion involved customised lingual orthodontic appliances, and essentially was not readily discernible.

According to research conducted by Roberts et al.,³⁶ the rate of molar traction can be as low as 0.2 mm per month. From a clinical perspective, the maxilla is more responsive to orthodontic treatment because it is primarily composed of trabecular bone. While the rate of tooth movement is the inverse of anchorage potential, the same physiologic principles apply.

Clinical studies using endosseous implants for anchorage have provided excellent opportunities to assess the rate of tooth movement through the dense cortical bone in the posterior mandible compared

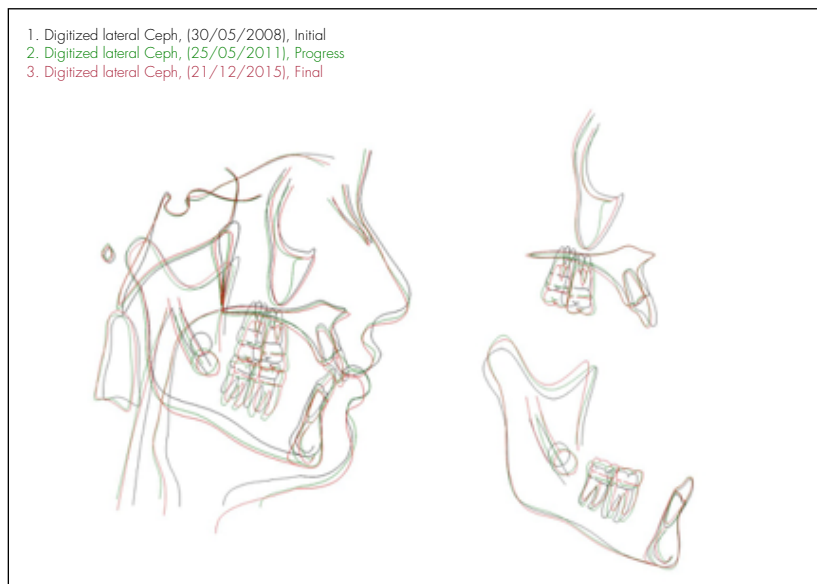


Figure 20. Superimposition of the pre- and post-treatment lateral cephalograms.

with the less dense trabecular bone of the posterior maxilla. The enhanced anchorage value of mandibular molars is related to the high density of bone formed as the leading roots are moved mesially. After a few months of mesial translation, the trailing roots engage the high-density bone formed by the leading root and the rate of tooth movement declines. Overall, the maximal rate of translation of the mid-root area through dense cortical bone is about 0.5 mm per month for the first few months, and subsequently the rate declines to less than 0.3 mm per month.

Multiple published case reports state that molar protraction to close the space of a congenitally absent second premolar is a challenging treatment procedure, with treatment durations of 40+ months (Goellner³⁷). The total treatment time for the present patient was 41 months (three years and five months), which is well within the reported average of two to four years for cases requiring molar mesialisation.³⁸

The treatment changes measured on the lateral cephalograms demonstrate that there were minimal changes in the maxillary and mandibular incisor angulations, suggesting preservation of anterior anchorage during the molar mesialisation process. One of the treatment objectives was to produce bodily movement or translation of the maxillary premolars and molars, rather than tipping of the crowns, to avoid potential future periodontal complications. To this end, the protractive forces were applied parallel to the centre of the resistance of the posterior dental



Figure 21. The Benefit Mini-Implant system and its constituent parts.

segment. The post-treatment panoramic radiograph demonstrates that the bodily movement of the posterior dental segment was achieved. A study using a finite element analysis has shown that directly applied force from a mini-screw to a posterior molar requiring mesialisation (direct anchorage) exerted lower strains on anchor teeth in comparison with indirect anchorage, particularly in the mandibular arch.³⁰

It was elected to provide the patient with an additional removable Essix© clear removable retainer, which would be worn up to the time of reshaping of her upper incisors, canines, and first premolars.

The salient and challenging characteristics of the present case included the significant amount of translatory tooth movement directed toward the anterior segment of the arch.³⁹ If the mesial movement of the molar crown is indicated during space closure, this can be achieved either by means of a space closing loop, a super elastic coilspring or a lingual arch. The problems related to the mesial movement of the roots are the same regardless of the appliance used. The line of action has to pass apical to the centre of resistance of the dental segment, and will always result in a combined uprighting mesial movement and extrusion.

In order to perform the uprighting combined with mesial movement, the vertical forces should be managed. Furthermore, the clinician must reinforce anchorage and neutralise undesirable vertical forces. In general, it is extremely difficult to displace a tooth

mesially and obtain simultaneous uprighting. When molars are advanced in such cases with skeletal anchorage systems, a tendency for extrusion and a reduction of the vertical overbite has been reported.

A combined molar uprighting and mesial movement is possible only if the line of force action is below the centre of resistance of the molar. This can be obtained by the use of power arms displacing the point of application and traction springs placed both labially and lingually. However, the problems with this appliance are that (1) it delivers extrusive forces to the molar, (2) the localisation of the line of action, with respect to the anterior unit, is such that anchorage loss may occur and, finally, (3) the moment, acting on the molar, is not very large. As a consequence, this system cannot be readily applied. In particular, in cases in which bilateral uprighting and mesial movements are desirable, anchorage loss is not permissible. To mitigate against this difficulty, the Mesialslider arms were adjusted in an apical direction prior to its insertion and engagement into the maxillary first molar bands. By so doing, a desired intrusive displacement of the maxillary molar teeth was achieved.

Wilmes et al.^{19,27} have suggested for convenience in routine practice that the arms of the Mesialslider may be adjusted chair-side. This negates the need for a dental laboratory and potentially saves the orthodontist in time and costs. As an alternative, an impression may be taken placing impression caps and laboratory analogues for manufacture of the Mesialslider on a plaster model. The Mesialslider has also been proposed for mesialising in cases with missing anterior teeth in addition to missing posterior teeth. Hence, the appliance has a wide variety of applications for dentoalveolar sagittal movements. Figure 21 illustrates images of the Benefit system and its constituent parts for individualisation in differing anchorage requirements. Although the present case used part L, which fits easily into the palatal tubes of the maxillary first molar bands without a laboratory soldering procedure, part K could have been used as well and soldered to the maxillary first molar bands.

Soldering part K to the maxillary first molar bands could provide a stiffer connection and, as a result, better bodily mesialisation of the molars.

Nevertheless, good bodily advancement of all maxillary premolars and molars was achieved in the present case.

All maxillary first premolars were mesialised into

alveolar areas associated with previous periodontal bone loss. Animal⁴⁰ and human experiments⁴¹ have shown that when a tooth is moved into a region of reduced alveolar volume, the periodontal apparatus of the moved tooth shows minimal periodontal alterations. Additionally, there can be a positive change in the width of the alveolar ridge.⁴¹ This was clearly seen in the presented case and ascribed to the excellent oral hygiene maintained by the patient throughout treatment.

The intrusion of molars using mini-implant supported biomechanics and associated root resorption has been investigated previously by volumetric computed tomography techniques.⁴⁰ The results suggest that there is an increased risk of mild to moderate root resorption caused by the intrusion particularly of the mesio-buccal root of the molars. Interestingly, no significant root resorption was seen affecting any teeth in the presented case when assessed on the panoramic radiograph. This may have been due to the reduced time in fixed appliances and/or differing amounts of intrusion when compared with other studies.

There were no complications seen or reported during and following orthodontic treatment. The patient was highly motivated throughout, and maintained good oral hygiene. At completion, sound occlusal interdigitation and intercuspation were established.

Conclusion

The successful orthodontic management and resolution of residual maxillary arch spacing in a patient presenting with congenitally absent lateral incisors is presented. The biomechanical plan consisted of the use of two maxillary mini-implants to maintain the stringent anchorage requirements during space closure, and the subsequent final detailing of the occlusion was performed with a fully customised lingual appliance (WIN). The total treatment duration of 41 months was well within reported averages for cases involving molar advancement. The desired objectives of a pleasing smile and facial aesthetics, functional occlusion and stability were achieved without complications.

References

1. Robertsson S, Mohlin B. The congenitally missing upper lateral incisor. A retrospective study of orthodontic space closure versus restorative treatment. *Eur J Orthod* 2000;22:697-710.
2. Zachrisson BU, Mjör IA. Remodeling of teeth by grinding. *Am J Orthod* 1975;68:545-53.

3. Thordarson A, Zachrisson BU, Mjör IA. Remodeling of canines to the shape of lateral incisors by grinding: a long-term clinical and radiographic evaluation. *Am J Orthod Dentofacial Orthop* 1991;100:123-32.
4. Costa A, Raffaini M, Melsen B. Miniscrews as orthodontic anchorage: a preliminary report. *Int J Adult Orthodon Orthognath Surg* 1998;13:201-9.
5. Freudenthaler JW, Haas R, Bantleon HP. Bicortical titanium screws for critical orthodontic anchorage in the mandible: a preliminary report on clinical applications. *Clin Oral Implants Res* 2001;12:358-63.
6. Kanomi R. Mini-implant for orthodontic anchorage. *J Clin Orthod* 1997;31:763-7.
7. Melsen B, Costa A. Immediate loading of implants used for orthodontic anchorage. *Clin Orthod Res* 2000;3:23-8.
8. Wilmes B. Fields of application of mini-implants. In: Ludwig B, Baumgaertel S, Bowman SJ, eds. *Innovative anchorage concepts. Mini-implants in orthodontics*. Berlin, New York: Quintessenz, 2008.
9. Berens A, Wiechmann D, Dempf R. Mini- and micro-screws for temporary skeletal anchorage in orthodontic therapy. *J Orofac Orthop* 2006;67:450-8.
10. Cheng SJ, Tseng IY, Lee JJ, Kok SH. A prospective study of the risk factors associated with failure of mini-implants used for orthodontic anchorage. *Int J Oral Maxillofac Implants* 2004;19:100-6.
11. Fritz U, Ehmer A, Diedrich P. Clinical suitability of titanium microscrews for orthodontic anchorage—preliminary experiences. *J Orofac Orthop* 2004;65:410-8.
12. Miyawaki S, Koyama I, Inoue M, Mishima K, Sugahara T, Takano-Yamamoto T. Factors associated with the stability of titanium screws placed in the posterior region for orthodontic anchorage. *Am J Orthod Dentofacial Orthop* 2003;124:373-8.
13. Karagiolidou A, Ludwig B, Pazera P, Gkantidis N, Pandis N, Katsaros C. Survival of palatal miniscrews used for orthodontic appliance anchorage: a retrospective cohort study. *Am J Orthod Dentofacial Orthop* 2013;143:767-72.
14. Ludwig B, Glasl B, Bowman SJ, Wilmes B, Kinzinger GS, Lisson JA. Anatomical guidelines for miniscrew insertion: palatal sites. *J Clin Orthod* 2011;45:433-41.
15. Lim HJ, Choi YJ, Evans CA, Hwang HS. Predictors of initial stability of orthodontic miniscrew implants. *Eur J Orthod* 2011;33:528-32.
16. Kim YH, Yang SM, Kim S, Lee JY, Kim KE, Gianelly AA et al. Midpalatal miniscrews for orthodontic anchorage: factors affecting clinical success. *Am J Orthod Dentofacial Orthop* 2010;137:66-72.
17. Wilmes B, Drescher D. Application and effectiveness of the Beneslider: a device to move molars distally. *World J Orthod* 2010;11:331-40.
18. Nienkemper M, Wilmes B, Pauls A, Yamaguchi S, Ludwig B, Drescher D. Treatment efficiency of mini-implant-borne distalization depending on age and second-molar eruption. *J Orofac Orthop* 2014;75:118-32.
19. Wilmes B, Nienkemper M, Nanda R, Lübberink G, Drescher D. Palatally anchored maxillary molar mesialization using the mesialslider. *J Clin Orthod* 2013;47:172-9.
20. Wilmes B, Nienkemper M, Ludwig B, Nanda R, Drescher D. Upper-molar intrusion using anterior palatal anchorage and the Mousetrapp appliance. *J Clin Orthod* 2013;47:314-20; quiz 328.
21. Wilmes B, Drescher D. Vertical periodontal ligament distraction—a new method for aligning ankylosed and displaced canines. *J Orofac Orthop* 2009;70:213-23.
22. Wilmes B, Nanda R, Nienkemper M, Ludwig B, Drescher D. Correction of upper-arch asymmetries using the Mesial-Distalslider. *J Clin Orthod* 2013;47:648-55.
23. Wilmes B, Nienkemper M, Ludwig B, Kau CH, Drescher D. Early Class III treatment with a hybrid hyrax-mentoplate combination. *J Clin Orthod* 2011;45:15-21.
24. Wilmes B, Olthoff G, Drescher D. Comparison of skeletal and conventional anchorage methods in conjunction with pre-operative decompensation of a skeletal class III malocclusion. *J Orofac Orthop* 2009;70:297-305.
25. Pjetursson BE, Brägger U, Lang NP, Zwahlen M. Comparison of survival and complication rates of tooth-supported fixed dental prostheses (FDPs) and implant-supported FDPs and single crowns (SCs). *Clinical Oral Implants Research* 2007;18:97-113.
26. Josefsson E, Brattström V, Tegsjö U, Valerius-Olsson H. Treatment of lower second premolar agenesis by autotransplantation: four-year evaluation of eighty patients. *Acta Odontol Scand* 1999;57:111-5.
27. Wilmes B, Drescher D. A miniscrew system with interchangeable abutments. *J Clin Orthod* 2008;42:574-80.
28. Wilmes B, Drescher D, Nienkemper M. A miniplate system for improved stability of skeletal anchorage. *J Clin Orthod* 2009;43:494-501.
29. Wilmes B, Katyal V, Willmann J, Stocker B, Drescher D. Mini-implant-anchored Mesialslider for simultaneous mesialisation and intrusion of upper molars in an anterior open bite case: a three-year follow-up. *Aust Orthod J* 2015;31:87-97.
30. Holberg C, Winterhalder P, Holberg N, Wichelhaus A, Rudzki-Janson I. Indirect miniscrew anchorage: biomechanical loading of the dental anchorage during mandibular molar protraction—an FEM analysis. *J Orofac Orthop* 2014;75:16-24.
31. Uribe F, Janakiraman N, Fattal AN, Schincaglia GP, Nanda R. Corticotomy-assisted molar protraction with the aid of temporary anchorage device. *Angle Orthod* 2013;83:1083-92.
32. Baik UB, Chun YS, Jung MH, Sugawara J. Protraction of mandibular second and third molars into missing first molar spaces for a patient with an anterior open bite and anterior spacing. *Am J Orthod Dentofacial Orthop* 2012;141:783-95.
33. Jacobs C, Jacobs-Müller C, Luley C, Erbe C, Wehrbein H. Orthodontic space closure after first molar extraction without skeletal anchorage. *J Orofac Orthop*. 2011;72:51-60.
34. Nagaraj K, Upadhyay M, Yadav S. Titanium screw anchorage for protraction of mandibular second molars into first molar extraction sites. *Am J Orthod Dentofacial Orthop* 2008;134:583-91.
35. Kyung SH, Choi JH, Park YC. Miniscrew anchorage used to protract lower second molars into first molar extraction sites. *J Clin Orthod* 2003;37:575-9.
36. Roberts WE, Marshall KJ, Mozsary PG. Rigid endosseous implant utilized as anchorage to protract molars and close an atrophic extraction site. *Angle Orthod* 1990;60:135-52.
37. Goellner P. Protraction of an upper second and third molar to replace a missing first molar. In: Cope JB, ed. *OrthoTADs: The Clinical Guide and Atlas*. 1st edn. Dallas: Under Dog Media, LP, 2007;419-22.
38. Hom BM, Turley PK. The effects of space closure of the mandibular first molar area in adults. *Am J Orthod* 1984;85:457-69.
39. Jung MH, Kim TW. Biomechanical considerations in treatment with miniscrew anchorage. Part 1: the sagittal plane. *J Clin Orthod* 2008;42:79-83.
40. Lindskog-Stokland B, Wennström JL, Nyman S, Thilander B. Orthodontic tooth movement into edentulous areas with reduced bone height. An experimental study in the dog. *Eur J Orthod* 1993;15:89-96.
41. Lindskog-Stokland B, Hansen K, Ekestubbe A, Wennström JL. Orthodontic tooth movement into edentulous ridge areas—a case series. *Eur J Orthod* 2013;35:277-85.
42. Li W, Chen F, Zhang F, Ding W, Ye Q, Shi J et al. Volumetric measurement of root resorption following molar mini-screw implant intrusion using cone beam computed tomography. *PLoS One* 2013;8:e60962.
43. Burstone CJ. The segmented arch approach to space closure. *Am J Orthod* 1982;82:361-78.