


jco

JOURNAL OF  
CLINICAL  
ORTHODONTICS

[www.jco-online.com](http://www.jco-online.com)

January 2019

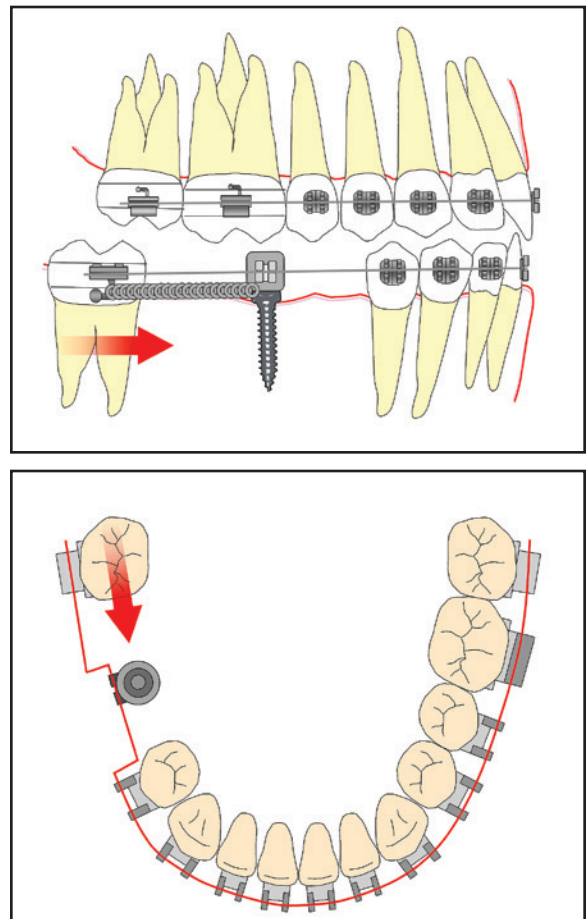


# Bridge Technique for Pre-Prosthetic Management of Wide Spaces

BENEDICT WILMES, DMD, MSD, PhD  
UWE SCHUMANN, DMD, DDS  
DIETER DRESCHER, DMD, MSD, PhD

**R**educing or closing a wide edentulous space in the posterior region of the mandible is a distinct challenge, especially in adult patients, because of the narrow, compact alveolar ridge. When the space is extremely wide and more than one tooth is missing, the orthodontic archwire may bend during mastication, interrupting tooth movement. A second problem is to reinforce anchorage enough to keep the anterior dentition from drifting distally during mesialization of the molars.

Over the past two decades, skeletal mini-implants have been increasingly integrated into treatment strategies because of their versatility, minimal invasiveness, and low cost.<sup>1-6</sup> The bridge technique was developed to facilitate lower molar mesialization in a patient with more than one missing tooth. A mini-implant of intermediate size serves as a pier in the middle of a wide space (Fig. 1), accomplishing two purposes:



**Fig. 1** Mini-implant functions as stabilization pier within wide space to prevent archwire bending during mastication and to control anchorage in sagittal dimension.



Dr. Wilmes



Dr. Schumann




Dr. Drescher

Dr. Wilmes is a Professor and Dr. Drescher is a Professor and Head, Department of Orthodontics, University of Düsseldorf, Düsseldorf, Germany. Dr. Schumann is in the private practice of orthodontics in Essen, Germany. E-mail Dr. Wilmes at wilmes@med.uni-duesseldorf.de.

1. Stabilization of the archwire to prevent excessive bending during mastication.
2. Anchorage control in the sagittal dimension during space closure.

Mini-implants with a diameter of 2mm or 2.3mm, such as the 2mm x 9mm Benefit\* mini-implant,<sup>7</sup> provide better stability than smaller mini-screws.<sup>8,9</sup> The self-drilling Benefit mini-implant can easily be inserted with a contra-angle screwdriver under topical or local anesthesia. A bracket

\*PSM Medical Solutions, Tuttlingen, Germany; www.psm.ms. Distributed in the U.S. by PSM North America, Indio, CA; www.psm-na.us.



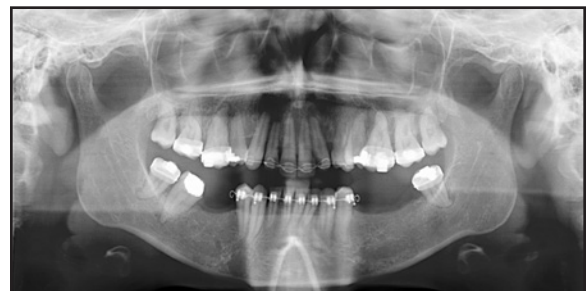**Fig. 2** Double-hex head of Benefit\* mini-implant allows bracket abutment to be affixed in 12 different positions.

abutment can be placed on top of the screw and fixed by an inner microscrew to allow a stable and safe connection with the archwire (Fig. 2). The double-hex head of the mini-implant enables the abutment to be fixed in 12 different positions.

Two cases demonstrate this technique.

### Case 1

A 37-year-old female patient presented with multiple missing teeth in the mandibular arch: the right second premolar and first molar and the left second premolar and first and second molars (Fig. 3). The remaining lower molars were tipped mesially. Clinical examination also found a missing upper left canine and a Class II malocclusion with

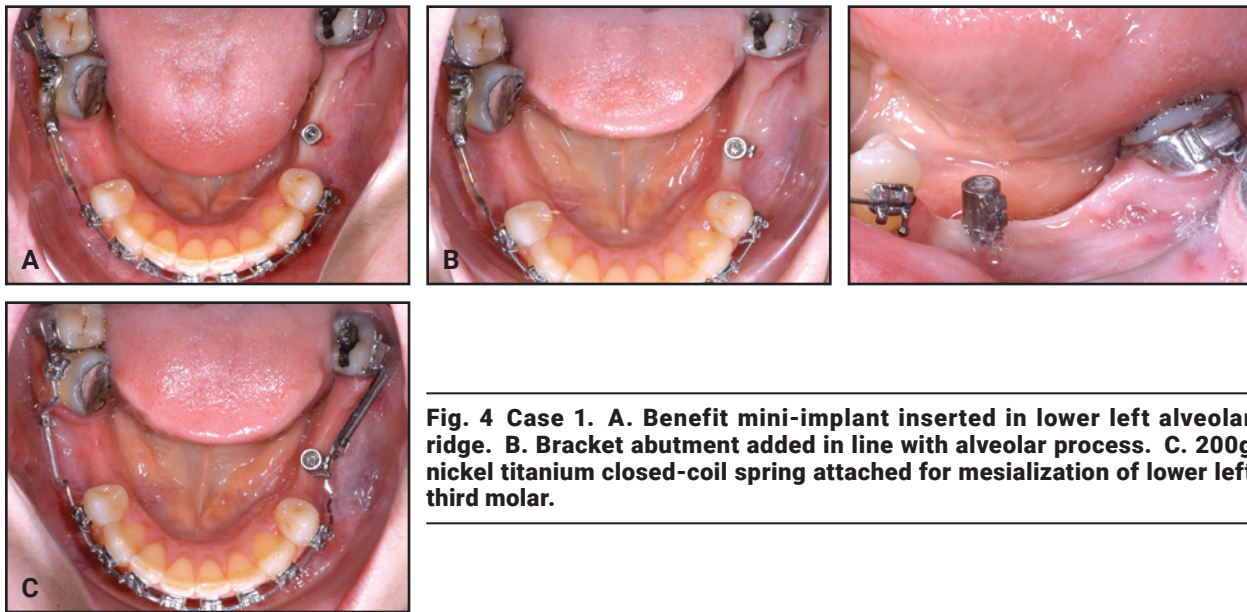


**Fig. 3** Case 1. 37-year-old female patient with multiple missing teeth in lower arch before treatment.

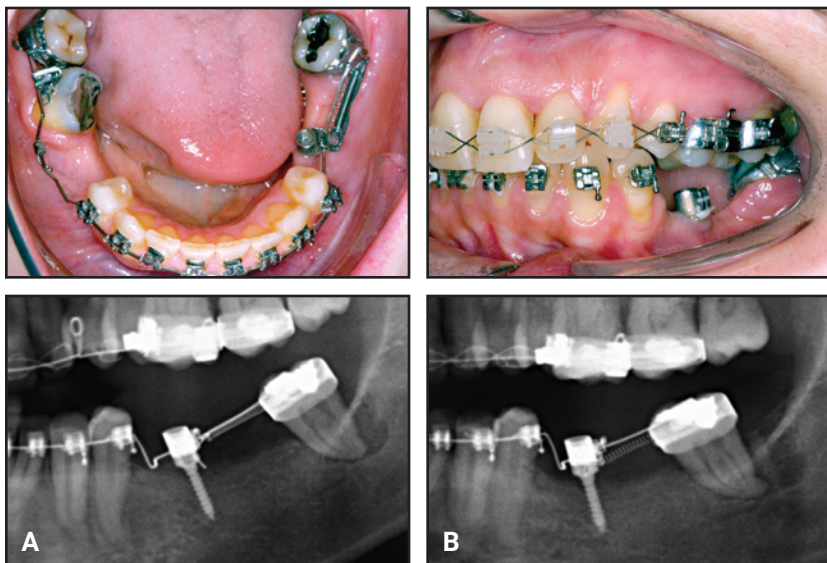
a deep bite, excessive overjet, bialveolar protrusion, and severe upper crowding.

To permit future prosthodontic restoration, the referring general dentist asked for molar up-righting and about 7mm of mesial movement of the lower left third molar. Leveling was carried out

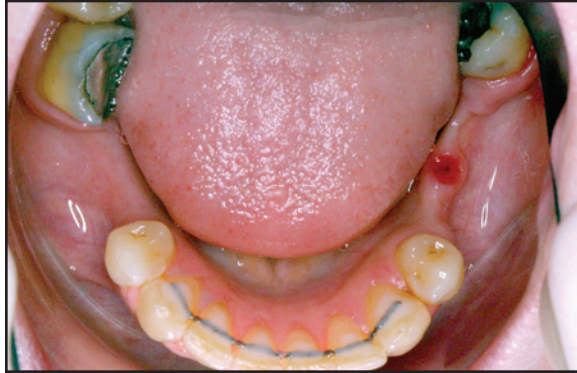over a year with a sequence of .014", .016", and .016" × .022" nickel titanium archwires. A Benefit mini-implant was then inserted in the lower left alveolar ridge, centered on the anticipated future space, in the same orientation as a dental implant would be (Fig. 4). A bracket abutment was affixed



**Fig. 4 Case 1. A. Benefit mini-implant inserted in lower left alveolar ridge. B. Bracket abutment added in line with alveolar process. C. 200g nickel titanium closed-coil spring attached for mesialization of lower left third molar.**



**Fig. 5 Case 1. Progress of lower left third molar mesialization. A. After five months of treatment. B. Mesialization completed after nine months of treatment.**



**Fig. 6 Case 1. Mini-implant removed one month after mesialization.**

so that the bracket slot was in line with the alveolar process. The main archwire was bent to fit into the slot of the bracket abutment, and a 200g nickel titanium closed-coil spring was attached for mesialization of the lower left third molar.

Five months later, the molar had been moved substantially (Fig. 5). After another four months, the desired mesialization was complete. All brackets were debonded one month later, and the mini-implant was removed (Fig. 6). Because the upper left canine was missing, a fixed upper retainer was bonded from the right canine to the left first premolar. A lower 3-3 lingual retainer was also bonded, and vacuum-formed removable retainers were delivered for use until the prosthetic restoration.

Six months after debonding, the general dentist was able to provide prosthetic rehabilitation (Fig. 7).

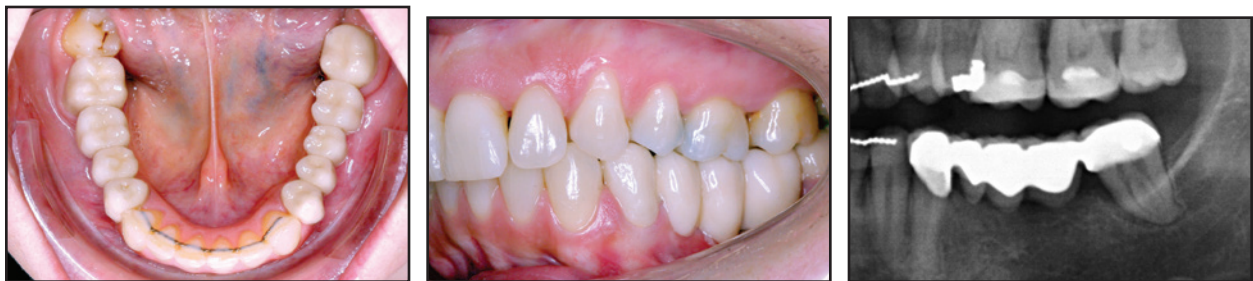## Case 2

A 23-year-old female patient presented with a mesially tipped lower left third molar and multiple missing teeth in the mandibular arch: the right first, second, and third molars and the left first and second molars (Fig. 8). Surgical correction was recommended because of her severe Class III malocclusion.

To facilitate prosthodontic restoration, the referring general dentist asked for molar uprighting and about 5mm of mesial movement of the lower left third molar. After four months of leveling, a Benefit mini-implant was inserted in the lower left alveolar ridge. A bracket abutment was affixed, and the main .016" × .022" stainless steel archwire was adapted to the slot of the abutment. A 200g nickel titanium closed-coil spring was attached for mesialization of the lower left third molar (Fig. 9). Three months later, to avoid molar rotation and resulting high friction, an elastic chain providing a lingual mesialization force was added (Fig. 10). Eight months after insertion of the mini-implant, a surgical mandibular setback was performed.

After 12 months of treatment, when the desired mesialization of the third molar had been achieved, all brackets were removed (Fig. 11). To retain the teeth adjacent to the space, the bracket abutment was replaced by an abutment with an .032" stainless steel wire<sup>7</sup> (Fig. 12). A lower 3-3 lingual wire was bonded, and a removable activator was delivered for one year of wear.

The general dentist began prosthetic rehabilitation immediately after debonding (Fig. 13).

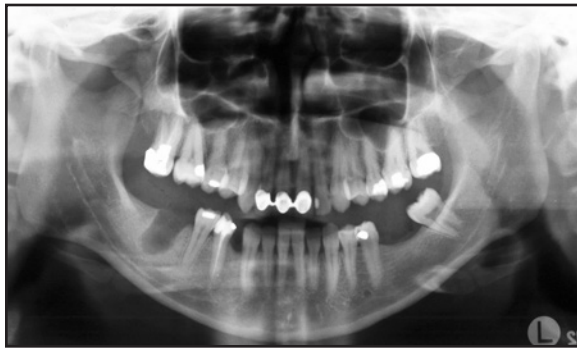


**Fig. 7 Case 1. Prosthetic rehabilitation completed six months after debonding.**

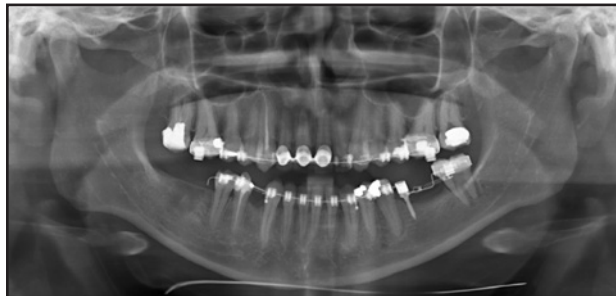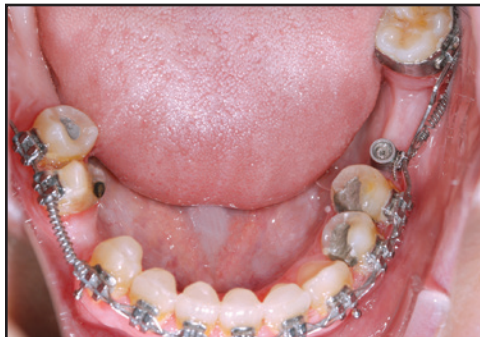**Conclusion**

Clinical studies have found that molars can be moved into edentulous areas while maintaining the level of periodontal tissues, even in areas with

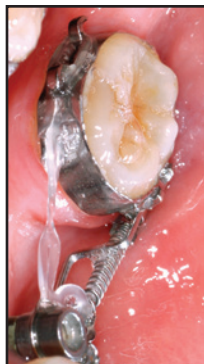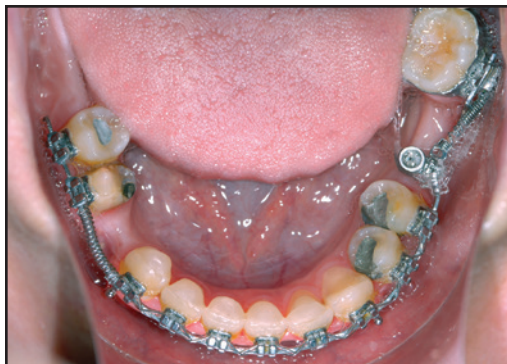reduced ridge dimensions.<sup>10,11</sup> The bridge technique demonstrated here addresses the two major concerns—wire damage due to mastication and anterior anchorage loss—by placing a mini-implant in the middle of the wide edentulous space.



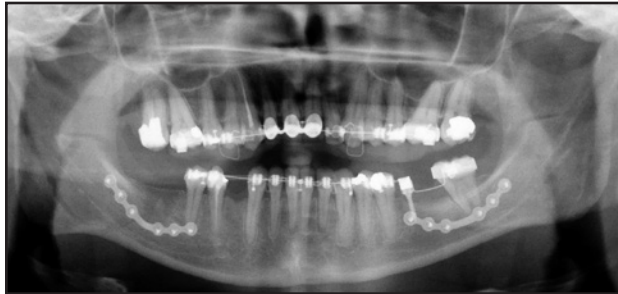**Fig. 8 Case 2. 23-year-old female patient with mesially tipped lower left third molar and multiple missing teeth in lower arch before treatment.**



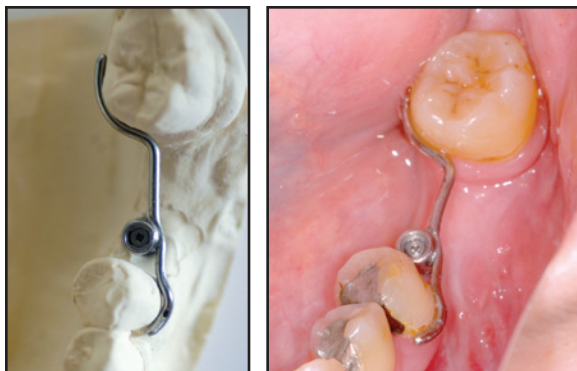
**Fig. 9 Case 2. After four months, Benefit mini-implant and bracket abutment placed, main orthodontic archwire adapted to slot, and 200g nickel titanium closed-coil spring attached for mesialization of lower left third molar.**



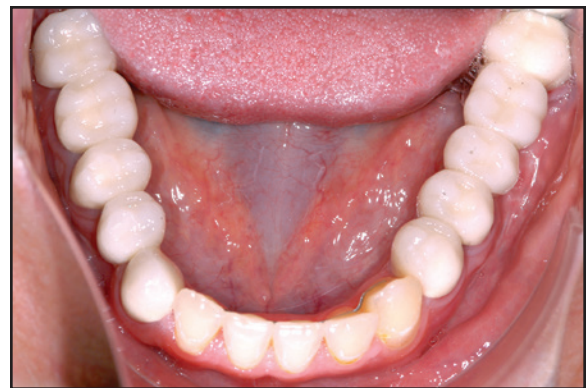**Fig. 10 Case 2. Elastic chain added to provide lingual mesialization force.**



**Fig. 11 Case 2. Mesialization completed after 12 months of treatment and surgical mandibular setback.**



**Fig. 12 Case 2. Skeletally anchored retention of lower left second premolar and third molar using Benefit abutment with .032" stainless steel wire.**



**Fig. 13 Case 2. Three months after debonding, with prosthetic rehabilitation completed.**

**REFERENCES**

1. Wilmes, B. and Drescher, D.: Application and effectiveness of the Beneslider: A device to move molars distally, *World J. Orthod.* 11:331-340, 2010.
2. Costa, A.; Raffainl, M.; and Melsen, B.: Miniscrews as orthodontic anchorage: A preliminary report, *Int. J. Adult Orthod. Orthog. Surg.* 13:201-209, 1998.
3. Freudenthaler, J.W.; Haas, R.; and Bantleon, H.P.: Bicortical titanium screws for critical orthodontic anchorage in the mandible: A preliminary report on clinical applications, *Clin. Oral Implants Res.* 12:358-363, 2001.
4. Kanomi, R.: Mini-implant for orthodontic anchorage, *J. Clin. Orthod.* 31:763-767, 1997.
5. Melsen, B. and Costa, A.: Immediate loading of implants used for orthodontic anchorage, *Clin. Orthod. Res.* 3:23-28, 2000.
6. Wilmes, B.: Fields of application of mini-implants, in *Mini-*

- Implants in Orthodontics: Innovative Anchorage Concepts*, ed. B. Ludwig, S. Baumgaertel, and J.S. Bowman, Quintessence Publishing Co., Inc., Hanover Park, IL, 2008, pp. 91-122.
7. Wilmes, B. and Drescher, D.: A miniscrew system with interchangeable abutments, *J. Clin. Orthod.* 42:574-580, 2008.
8. Wilmes, B.; Rademacher, C.; Olthoff, G.; and Drescher, D.: Parameters affecting primary stability of orthodontic mini-implants, *J. Orofac. Orthop.* 67:162-174, 2006.
9. Wilmes, B.; Ottenstreuer, S.; Su, Y.Y.; and Drescher, D.: Impact of implant design on primary stability of orthodontic mini-implants, *J. Orofac. Orthop.* 69:42-50, 2008.
10. Wehrbein, H.; Riess, H.; Meyer, R.; Schneider, B.; and Diedrich, P.: Bodily movement of teeth in atrophic jaw segments, *Dtsch. Zahnärztl. Z.* 45:168-171, 1990.
11. Lindskog-Stokland, B.; Hansen, K.; Ekestubbe, A.; and Wennström, J.L.: Orthodontic tooth movement into edentulous ridge areas—A case series, *Eur. J. Orthod.* 35:277-285, 2013.